

# P Elevator: An Innovatively Designed Elevator for Extraction of Third Molars

Pradeep SINGH<sup>1</sup>, Shui Sheng XIAO<sup>1</sup>, Deepal Haresh AJMERA<sup>2</sup>

**Objective:** *To modify the conventional straight elevator with a unique and innovative design in respect to approach and accessibility during extraction for patients with abrasions around corners of the mouth and with thick buccal mucosa, without causing overstretching of angles of the mouth.*

**Methods:** *The shank of the straight elevator in the shape of a 'U' was modified, giving it a shape similar to 'P' in the English alphabet hence it is named the P Elevator. The P elevator utilises a 'U' shaped bend in the shank of the conventional straight elevator making space for the buccal soft tissues and the angle of the mouth, to accommodate properly in the 'U' shank. The application of this elevator in the successful removal of third molars is described.*

**Results:** *Two hundred patients underwent extraction of third molars with the P elevator including 166 patients with disimpaction of all third molars, 23 patients with abrasion around the angle of the mouth, and 11 patients with thick buccal mucosa. Satisfactory results were obtained in all the cases with no postoperative complications.*

**Conclusion:** *The P elevator permits prudent, meticulous, innovative and proficient extraction of third molars in patients with thick buccal mucosa and abrasions around the angle of the mouth, without overstretching the corners of the mouth. We introduce novel applications of the P elevator in third molar extraction that provide substantial advantages over a conventional straight elevator.*

**Key words:** *abrasions of angles of the mouth, elevators, thick buccal mucosa, third molar extraction, overstretching of corners of the mouth*

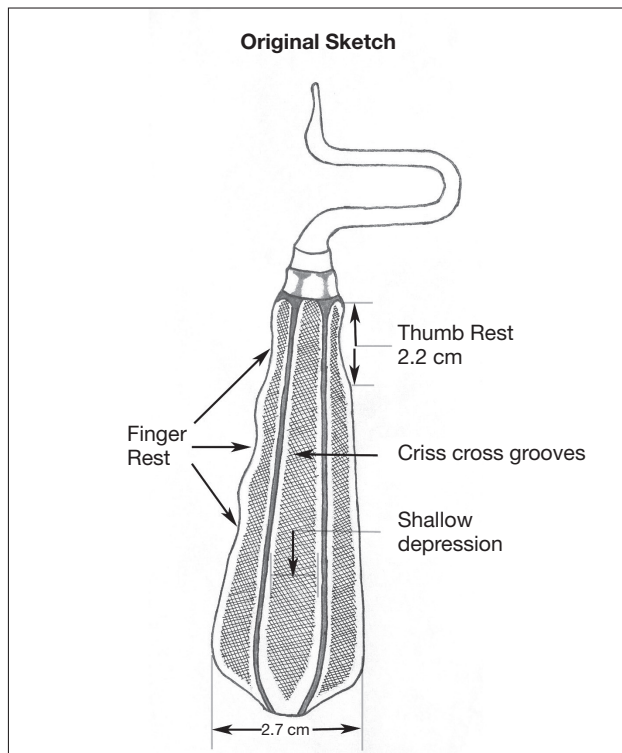
A variety of new instruments and techniques are revolutionising the fields of oral and maxillofacial surgery and dentistry as a whole<sup>1</sup>. Elevators, which originate back to the 16th century, are one of the most eminent tools of contemporary dentistry that are being used in customary extraction procedures. Prevailing elevators have an extended history in dental practice. The use

of elevators in exodontia dates back to 1122<sup>2</sup>. Elevators have evolved from 'repoussoirs', 'The Expluser', 'Gorz's geissfuss' to 'Geissfuss mit Haken'<sup>2</sup>. The evolution of surgical instrumentation is a reflection of our collective surgical experience<sup>3</sup>. Time and again modifications in the design of elevators have led to modern day elevators. Elevators are used to luxate teeth, expand alveolar bone and to remove broken or surgically sectioned roots from their sockets. Used in appropriate circumstances, these elevators approach the ideal conditions for safe effective exodontia<sup>4</sup>. In the process of a simple extraction, surgeons must exercise a great deal of finesse and a certain degree of controlled force to be able to deliver a simple tooth extraction<sup>5</sup>. Although prevailing elevators are quite efficient, incessant modifications in their design will require time. During the extraction of the third molars, we noticed that the conventional straight elevator is not as efficient in patients with thick

1 Department of Oral and Maxillofacial Surgery, The Affiliated Hospital of Stomatology, Chongqing Medical University, Chongqing, P.R. China.

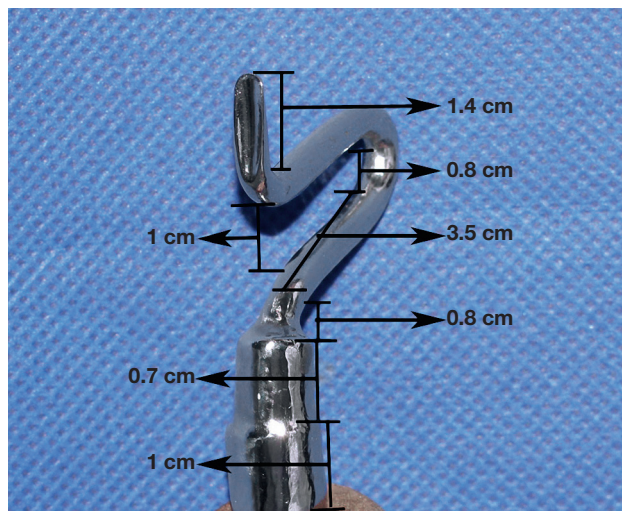
2 Department of Orthodontics and Dentofacial Orthopedics, The Affiliated Hospital of Stomatology, Chongqing Medical University, Chongqing, P.R. China.

**Corresponding author:** Dr Shui Sheng XIAO, Department of Oral and Maxillofacial Surgery, The Affiliated Hospital of Stomatology, Chongqing Medical University, Shangqingsi Road 5, Yuzhong District, Chongqing 400015, P.R. China. Tel: 86-13594620105; Fax: 86-023-88860222; Email: xiaoss66@hotmail.com



**Fig 1** Lateral view of the elevator with dimensions, thumb rest, finger rests and criss-cross grooves on the handle. Shallow depressions and criss-cross grooves are evident here.

buccal mucosa and abrasions around the angles of the mouth. Also it causes discomfort to the patients due to overstretching of corners of the mouth by the elevator when gaining access to the third molars. The objective of this paper is to introduce a distinctive modification in the



**Fig 2** U shank with dimensions and a tip, with a concave surface.

design of the conventional straight elevator that can be a highly proficient instrument for the extraction of third molars in patients with thick buccal mucosa and abrasions of corners of the mouth; therefore concurrently minimising the discomfort caused due to overstretching of corners of the mouth.

### Materials and methods

All dental elevators consist of a basic design and several components: a) handle; b) shank; c) tip/ blade. They work on the principles of 1) lever; 2) wedge; and 3) wheel and axle. Numerous modifications were carried out on the handle, shank, and tip depending upon the clinician's needs, resulting in contemporary elevators. The principal design of our elevator was similar to the conventional straight elevator i.e. a) handle; b) shank; and c) tip /blade (Fig 1). We modified the shank of the straight elevator in the shape of a 'U' giving it a shape similar to 'P' in the English alphabet. The P elevator works on the principles of 1) Lever and 2) Wedge. The tip and handle have a common axis and the centre of the tip is in a straight line with the centre of the handle. The dimensions of the P elevator are provided in Figure 1 and Figure 2.

The length of the handle was 9.00 cm (Fig 1), which gradually tapers towards the shank. The diameter of the handle at the base was 2.70 cm (Fig 1) and the diameter of the small flat portion at the base was 0.80 cm. The length of the thumb rest in the handle was 2.20 cm (Fig 1). In order to provide better grip to the operator, the surface of the handle was provided with longitudinal shallow depressions parallel to the long axis of the elevator rather than making it flat, as seen in Figure 1. To further enhance the grip the shallow depressions in the handle were provided with intercrossing grooves (Fig 1). On the surface, contralateral to the surface of the thumb rest, shallow depressions were made for the three gripping fingers of the operator's hand (Fig 1). These three depressions worked as finger rests for the operator's fingers.

The length of the arms of the U shank was 3.50 cm, the distance between the two arms of the U shank at the closed end was 0.80 cm, and at the open end it was 1.00 cm (Fig 2). The shank took a smooth right-angled turn from the handle and continued in the form of the 'U'. The shank then took a right-angled turn to form the tip of the elevator. The length of the tip was 1.40 cm (Fig 2). The tip of the elevator was similar to the conventional straight elevator with a convex surface and concave surface, with the concave surface facing towards the tooth to be extracted (Fig 2). Due to a lack

of resources and funds, the handle of the elevator was made with wood (Fig 3) and not stainless steel, which is used in the actual design of the elevator (Fig 1). Given that it was a primary instrument the handle was made with wood, but in the final product it will be made with stainless steel.

The operator can hold the elevator as shown in Figure 4 with the open end of the U shank facing towards and parallel to the labial and buccal soft tissues therefore making the handle and tip perpendicular to the buccal soft tissues (Figs 5 and 6).

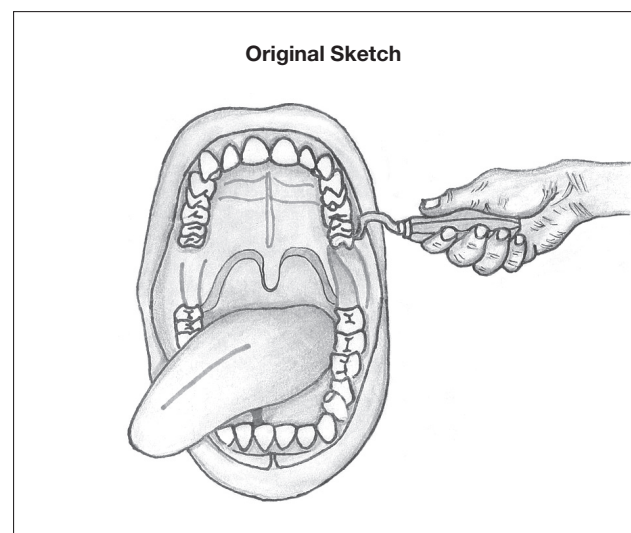
The elevator works on a) lever principle and b) wedge principle, by slowly wedging into the periodontal ligament space, and making use of interdental bone as fulcrum<sup>6</sup>, similar to the conventional straight elevator. The tip is inserted into the interdental space with its concave surface towards the tooth to be extracted and the concave surface facing the adjacent tooth, making use of interdental bone as fulcrum, slowly wedging into the periodontal ligament space and luxating, which allows for extraction of the tooth. This elevator can be used with equal efficiency in all the four quadrants, therefore is beneficial when extracting all the four wisdom molars without discomfort to the patient.

## Results

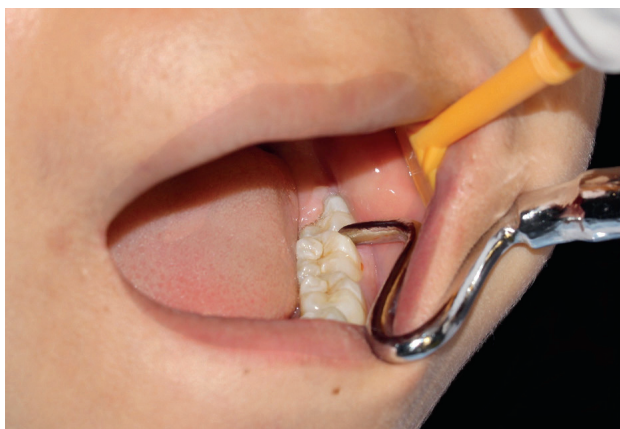The P elevator was used in the extraction of third molars in 200 patients. Before using it on patients, the elevator was sterilised and packed in 3M Steri Dual ECO packets. Out of 200 patients, 23 patients had chapped lips and abrasions around angles of the mouth, 11 patients



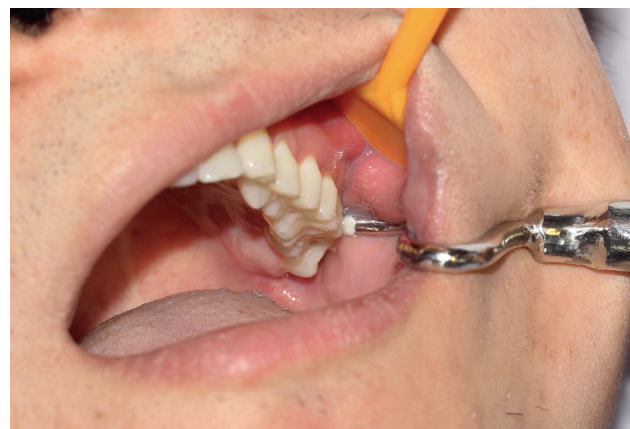**Fig 3** P Elevator with wooden handle.



**Fig 4** Operator holding the elevator and showing its use.



**Fig 5** Use of the elevator intraorally for extraction of a mandibular third molar (38), which shows the U shank accommodating the buccal soft tissue. Note that mouth mirrors were used for the purpose of obtaining a better photograph and not for retraction while using the elevator.



**Fig 6** Use of the elevator intraorally for extraction of a maxillary third molar (28).

had thick buccal mucosa and 166 patients had undergone disimpaction of all third molars in either a single appointment or two appointments. Other than common postoperative complications related to the disimpaction procedure, no postoperative complications specifically caused by the P elevator were noticed in any of the patients and the experience of patients with the P elevator was comfortable and satisfactory.

## Discussion

At the Department of Oral and Maxillofacial Surgery, The Affiliated Hospital of Stomatology, Chongqing Medical University, Chongqing, disimpaction of the third molars were performed in 200 patients, age group 17 to 55 years old, with the help of the P elevator. Patients included for disimpaction had either thick buccal mucosa, recurrent abrasions around corners of the mouth or a previous uncomfortable experience of extraction due to overstretching of angles of the mouth by the elevator, when attempting to gain access to the third molars. Reasons for undergoing disimpaction usually are recurrent pericoronitis, endodontic reasons, periodontal problems, orthodontic reasons, or prophylactic removal<sup>7</sup>. While extracting the third molars we noticed that in patients with thick buccal mucosa, it is difficult to retract the buccal tissues in order to gain access to the third molars, especially in maxillary molars. Thickening of the buccal mucosa can be a normal feature for heavily built patients with a thick musculature or it can be pathological as seen in oral submucous fibrosis<sup>8,9</sup>. Thick buccal mucosa poses difficulties in extraction as it lacks elasticity and is difficult to retract. If the retraction is not sufficient, accessibility is compromised which makes removal of the third molars more difficult. We also noticed that patients who suffered abrasions around the corners of the mouth and chapped lips also complained of discomfort after extraction. Abrasions around the corners of the mouth have been noticed in patients with angular cheilitis<sup>10</sup>. Retraction of corners of the mouth causes fanatical discomfort to such patients. In order to compare the patient's experience with the straight elevator and the P elevator, we performed extraction of the third molars of the ipsilateral side (either left or right/either the first and fourth quadrant or the second and third quadrant) with the straight elevator on one appointment and the extraction of the third molar of the other side with the P

elevator on the next appointment. Few patients underwent extraction of all the third molars on the same visit. Also in these patients, the straight elevator was used on one side and the P elevator was used on the other side. Patients complained of discomfort due to overstretching of the angles of the mouth with the use of the conventional straight elevator. Patients' experience with the P elevator was much more comfortable compared to the straight elevator and with equivalent efficacy. The U shank of the P elevator accommodates buccal soft tissues easily and also causes minimal discomfort at the corners of the mouth.

## Conclusion

The results of the extractions performed with the P elevator indicated that thick buccal mucosa and abrasions around corners of the mouth pose difficulties in retraction, which makes extraction difficult due to compromised accessibility. This also indicates that the P elevator is a proficient instrument when it comes to extracting third molars without causing overstretching and discomfort to the patient, thus making extraction minimally traumatic.

## References

1. Weiss A, Stern A, Dym H. Technological advances in extraction techniques and outpatient oral surgery. *Dent Clin North Am* 2011;55:501–513.
2. Bussell MA, Graham RM. The history of commonly used dental elevators. *Br Dent J* 2008;205:505–508.
3. Assael LA. The effect of design on performance in surgical practice: improving instrumentation. *J Oral Maxillofac Surg* 2004;62:397–398.
4. Kandler HJ. The design and construction of dental elevators. *J Dent* 1982;10:317–322.
5. Dym H, Weiss A. Exodontia: tips and techniques for better outcomes. *Dent Clin North Am* 2012;56:245–266.
6. Andersson L, Kahnberg KE, Pogrel MA (eds). *Oral and Maxillofacial Surgery* ed 1. Oxford: Wiley-Blackwell, 2010:139.
7. Godfrey K. Prophylactic removal of asymptomatic third molars: a review. *Aust Dent J* 1999;44:233–237.
8. Auluck A, Rosin MP, Zhang L, Sumanth KN. Oral submucous fibrosis, a clinically benign but potentially malignant disease: report of 3 cases and review of the literature. *J Can Dent Assoc* 2008;74:735–740.
9. Jayanthi V, Probert CS, Sher KS, Mayberry JF. Oral submucosal fibrosis -- a preventable disease. *Gut* 1992;33:4–6.
10. Shafer WG, Levy BM, Hine MK, Rajendran R, Siva Pathasundharam B. *Shafer's textbook of oral pathology* ed 6. New Delhi: Elsevier, 2009:916–917.