

# Prevalence of Preeruptive Intracoronal Radiolucency in Chinese Children from Panoramic Radiographs

Yun WANG<sup>1,2</sup>, Jie CHEN<sup>1</sup>, He LIU<sup>1</sup>

**Objective:** To determine the prevalence of preeruptive intracoronal dentin defects in Chinese children from panoramic radiographs, and describe the imaging characteristics of these lesions.

**Methods:** A total of 707 panoramic radiographs with 8,171 unerupted permanent teeth were examined. Each unerupted tooth was examined with regard to the absence or presence of radiolucencies within the dentin of the crown. The location and size of the lesions were recorded. Also whether the lesion communicated with the pulp was noted.

**Results:** The prevalence of intracoronal radiolucency in the subjects was 0.85%, and the tooth prevalence of the anomaly was 0.7%.

**Conclusion:** Panoramic radiographs may help in detecting the preeruptive intracoronal defect.

**Key words:** intracoronal radiolucency, panoramic radiograph, tooth development

A preeruptive intracoronal radiolucency is a lesion in the crown of an unerupted tooth. On radiographs, these lesions appear as circumscribed radiolucencies within the coronal dentin, and adjacent to the dentino-enamel junction (DEJ)<sup>1</sup>. It is usually symptomless and is discovered only as an incidental radiographic finding, or is present at the time of eruption<sup>2</sup>. However, pulpal and periapical diseases related to this lesion were also reported<sup>3,4</sup>.

This condition was first reported in 1941 by Skillen<sup>5</sup>. As the lesions often resemble dental caries, the term 'preeruptive caries' has been occasionally applied<sup>5-7</sup>. Most of the literature related to these lesions are reports of individual cases. Currently, there are only three studies that have reported on the prevalence of

the condition<sup>8-10</sup>. One of those studies was carried in Malaysia, using panoramic radiographs to diagnose these lesions<sup>10</sup>, while the other two were carried out in Australia, utilising bitewing radiographs and panoramic radiographs respectively<sup>8,9</sup>.

The aim of the present study was to determine the prevalence of preeruptive intracoronal dentin defects in Chinese children from panoramic radiographs, and to describe the imaging characteristics of these lesions.

## Methods

The panoramic radiographs, taken in the period between 2000 and 2009 in the Department of Radiology, Peking University School and Hospital of Stomatology, were examined. Based on medical records, children with systematic diseases, jaw diseases and history of orthodontic treatment were excluded. Photographs with poor quality were also excluded.

Only unerupted teeth were assessed. All unerupted teeth in each radiograph were examined and totalled. Each unerupted tooth was examined with regard to the absence or presence of radiolucencies within the dentin of the crown. The affected teeth were recorded. The location of each lesion was noted with regard to wheth-

1 Department of Pediatric Dentistry, Peking University School and Hospital of Stomatology, Beijing, P.R. China.

2 Department of Pediatric Dentistry, School of Stomatology, Tongji University, Shanghai, P.R. China.

**Corresponding author:** Dr He LIU, Department of Pediatric Dentistry, Peking University School and Hospital of Stomatology, #22 Zhongguancun Nandajie, Haidian District, Beijing 100081, P.R. China. Tel: 86-10-82195361; E-mail: heliu69@126.com

**Table 1** Subject prevalence of preeruptive dentin defects

	Defects Present		No Defects	
	Number	%	Number	%
Female	2	0.53%	373	99.47%
Male	4	1.20%	328	98.80%
Total	6	0.85%	701	99.15%

**Table 2** Radiographic features of preeruptive dentin radiolucencies within the crown

	Gender	Tooth position	Location of defect in dentin	Size of defect*	Communication with pulp chamber	Periapical lesion of the primary precursor	With congenital missing teeth
1	Female	43	Central	II	No	No	No
2	Male	16	Distal	I	No	No	No
3	Male	47	Distal	II	No	No	No
4	Male	17	Mesial	I	No	No	No
5	Female	37	Distal	I	No	No	No
6	Male	44	Mesial	III	No	No	Yes

\*I  $\leq$  1/3 relative dentin thickness, II  $\leq$  2/3 relative dentin thickness, III  $>$  2/3 relative dentin thickness

er it was on the central, mesial, or distal aspect of the crown. The size of each defect related to coronal dentin thickness was also noted to whether it was within one-third dentin thickness, or two-thirds dentin thickness, or extended through the full dentin thickness. In addition, whether the lesion communicated with the pulp was also noted. The same examination was re-performed by the same paediatric dentist a month later.

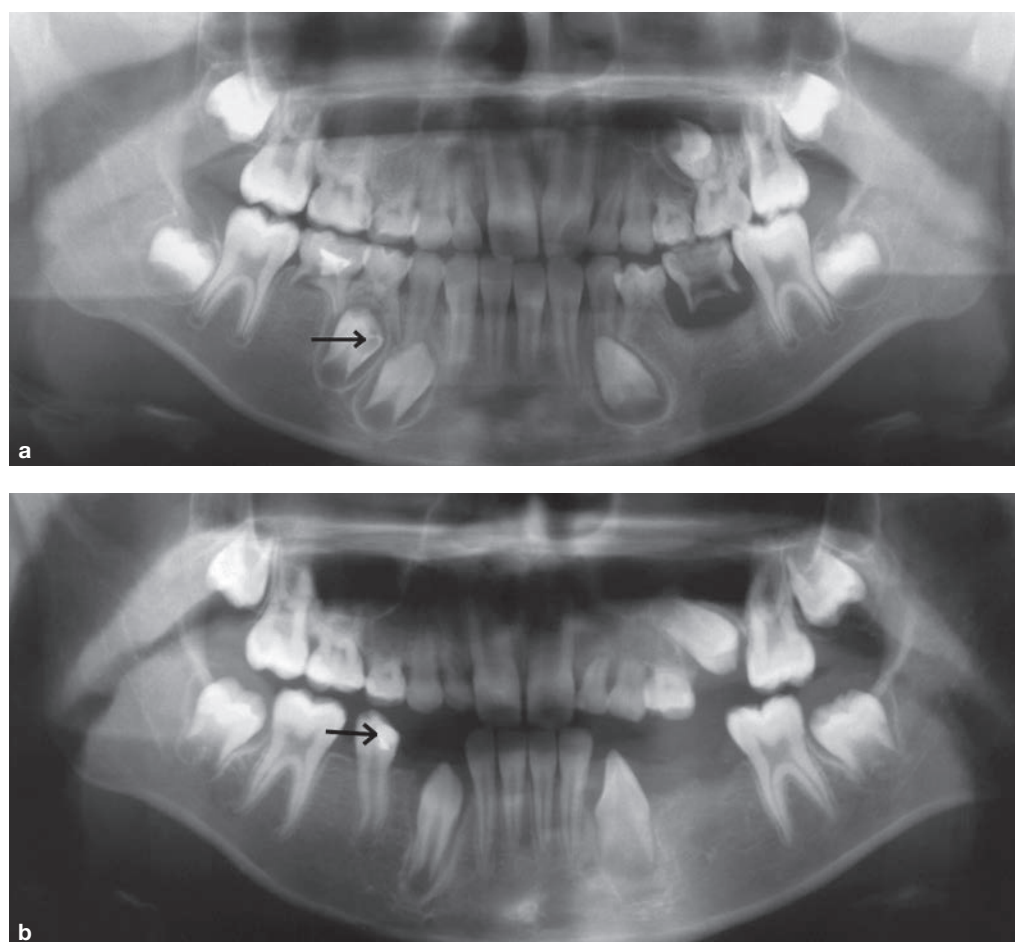
## Results

All the radiographs selected were from Chinese children aged between 3.6 to 12.5 years old. A total of 707 panoramic radiographs with a total of 8,171 unerupted teeth were examined. Of these subjects, 332 were from males (average age 9.4 years) and 375 from females (average age 9.3 years). Of the radiographs, 13.3% were from the subjects with congenital missing teeth (47 males and 47 females).

Six teeth, from six subjects respectively, showed preeruptive intracoronal radiolucency. Therefore, the subject prevalence was 0.85% (Table 1), and the tooth prevalence was 0.7%. Table 2 lists the features of the lesion in each tooth. In our result, the preeruptive intracoronal dentin defects were most often seen in the mandibular second molar (2 out of 6).

All the preeruptive dentin defects in the present study were located in the dentin, just beneath the DEJ. About 50% of the defects were located on the distal aspect of the unerupted tooth.

The size of the defects was classified relative to the thickness of dentin. It was noted that 3 (50%) were less than one-third relative dentin thickness, 2 (33.3%) were between one-third and two-thirds relative dentin thickness, and 1 (16.7%) had extended to greater than two-thirds of the thickness of the coronal dentin. No communication with the pulp chamber was noted in the affected teeth.



**Fig 1** The radiolucent dentin defect was located in the unerupted 44. The primary precursor has no periapical lesion. There are 10 teeth that are congenitally missing. The lesion was finally restored when the tooth erupted. **a** before eruption; **b** after eruption.

Two of the affected teeth had primary precursors, but no periapical lesion of the primary tooth was noted. The other four affected teeth were permanent molars. Interestingly, one of the subjects was affected with congenitally missing teeth (Fig 1). This patient had pictures taken separately before and after eruption. The lesion was finally restored.

### Discussion

In a review of the literature, four aetiologies have been proposed to explain the radiolucent lesions within the dentins of unerupted teeth:

- Apical inflammation of primary teeth<sup>11</sup>
- Caries<sup>6</sup>
- Developmental abnormality<sup>12</sup>
- Internal or external resorption<sup>5,13-17</sup>

However, the cause of these defects remain unclear. Currently, the widely accepted theory is dentin resorption. The theory is supported by histological studies that showed multinuclear giant cells, osteoclasts, resorptive lacunae, and other chronic inflammatory cells in the lesions<sup>5,13-17</sup>.

The present study found that 0.85% of subjects showed preeruptive dentin defects and the prevalence of teeth was 0.7%. The prevalence from our study is therefore much lower than that reported by Seow et al<sup>8</sup>, which was 3% by subjects and 0.5% by teeth, and Nik et al<sup>10</sup>, which was 27.3% by subjects and 2.1% by teeth. The reason for the difference in prevalence is likely to be due to ethnic difference.

In this study it was observed that all the defects were noted in the dentin just below the DEJ. It is similar to the previous reports. However, the defects were more frequently observed in the distal aspect (50%) of the crown, not as reported in the mesial or central aspect<sup>8,10</sup>. It was reported that the highest prevalence is

noted in the maxillary and mandibular first permanent molars<sup>8,10</sup>. While in our study, half of the cases affected the second permanent molar.

Congenital missing teeth were also present in one of the patients in this research. Wood<sup>7</sup> reported 16 sporadic cases of intracoronal radiolucency, 25% of which exhibited developmental disturbances in the number of teeth. However, the number of involved children was too small to conclude the relationship of intracoronal radiolucency and congenital missing teeth.

Panoramic radiographs are useful in paediatric dentistry, especially for screening developmental anomalies. As we showed here, panoramic radiographs also play an important role in detecting preeruptive dentin defects. The teeth with preeruptive intracoronal radiolucencies may be mistakenly diagnosed as caries when the teeth erupt into the oral cavity, while regular examination may help to make a definite diagnosis.

Regarding the clinical treatment of preeruptive dentin defects, there is lack of consensus in the management of these lesions. The majority of experts<sup>2,4,11,18-22</sup> suggested to surgically expose the affected tooth and use either a permanent or temporary restoration. It was also suggested by some paediatric dentists<sup>12,23-28</sup> to periodically observe the patients until the affected teeth erupt and then give treatment. Besides, some affected teeth were extracted because of orthodontic or other reasons<sup>14,16,17,25,28-30</sup>. We think it is important to determine whether the lesion is progressive or static, by taking radiographs periodically. If the lesion is progressive, it is important to surgically intervene and prepare a restoration, in order to arrest the progression of the resorptive process and avoid the involvement of the pulp. Otherwise, intervention could be postponed until eruption and the tooth will not be jeopardized.

## Conclusions

The presence of preeruptive intracoronal radiolucency may be detected from panoramic radiographs. The prevalence of the condition by subject was 0.85% and the tooth prevalence was 0.7% in Chinese children. Increasing the awareness of this defect is important to detect the lesion and allow timely treatment.

## References

- Davidovich E, Kreiner B& Peretz B. Treatment of severe pre-eruptive intracoronal resorption of a permanent second molar. *Pediatric Dent* 2005;27:74-77.
- Holan G, Eidelman E, Mass E. Pre-eruptive coronal resorption of permanent teeth: report of three cases and their treatments. *Pediatric Dent* 1994;16:373-377.
- Kunz GT. Pre-eruptive intracoronal lesion of a mandibular first molar. *Gen Dent* 1997;45:574-576.
- Dowling PA, Fleming P, Corcoran F. A case report of pre-eruptive coronal resorption in a mandibular canine. *Dent Update* 1999;26:444-445.
- Skillen WG. So-called "intrafollicular caries" III. *Dent J* 1941;10:307-308.
- Baab DA, Morton TH, Page RC. Caries and periodontitis associated with an unerupted third molar. *Oral Surg Oral Med Oral Pathol* 1984;58:428-430.
- Wood PF, Crozier DS. Radiolucent lesions resembling caries in the dentine of permanent teeth. A report of sixteen cases. *Aust Dent J* 1985;30:169-173.
- Seow WK, Lu PC, McAllan LH. Prevalence of pre-eruptive intracoronal dentin defects from panoramic radiographs. *Pediatric Dent* 1999;21:332-339.
- Seow WK, Wan A, McAllan LH. The prevalence of pre-eruptive dentin radiolucencies in the permanent dentition. *Pediatr Dent* 1999;21:26-33.
- Nik NN, Abul Rahman R. Pre-eruptive intracoronal dentin defects of permanent teeth. *J Clin Pediatr Dent* 2003;27:371-375.
- Muhler J. The effect of apical inflammation of primary teeth on dental caries in the permanent teeth. *J Dent Child* 1957;24:209-210.
- Walton JL. Dentin radiolucencies in unerupted teeth: report of two cases. *ASDC J Dent Child* 1980;47:183-186.
- Mueller BH, Lichty GC 2nd, Tallerico ME, et al. "Caries-like" resorption of unerupted permanent teeth. *J Pedod* 1980;4:166-172.
- Klambani M, Lussi A, Ruf S. Radiolucent lesion of an unerupted mandibular molar. *Am J Orthod Dentofacial Orthop* 2005;127:67-71.
- Savage NW, Gentner M, Symons AL. Preeruptive intracoronal radiolucencies: review and report of case. *ASDC J Dent Child* 1998;65:36-40.
- DeSchepper EJ, Haynes JI, Sabates CR. Preeruptive radiolucencies of permanent teeth: report of a case and literature review. *Quintessence Int* 1988;19:157-160.
- Blackwood HJ. Resorption of enamel and dentine in the unerupted tooth. *Oral Surg Oral Med Oral Pathol* 1958;11:79-85.
- Skaff DM, Dilzell WW. Lesions resembling caries in unerupted teeth. *Oral Surg Oral Med Oral Pathol* 1978;45:643-646.
- Rankow H, Croll TP, Miller AS. Preeruptive idiopathic coronal resorption of permanent teeth in children. *J Endod* 1986;12:36-39.
- Ignelzi MA Jr, Fields HW, White RP, et al. Intracoronal radiolucencies within unerupted teeth. Case report and review of literature. *Oral Surg Oral Med Oral Pathol* 1990;70:214-220.
- Seow WK, Hackley D. Pre-eruptive resorption of dentin in the primary and permanent dentitions: case reports and literature review. *Pediatric Dent* 1996;18:67-71.
- O'Neal KM, Gound TG, Cohen DM. Preeruptive idiopathic coronal resorption: a case report. *J Endod* 1997;23:58-59.
- Coke JM, Belangaer GK. Radiographic caries-like distal-surface enamel defect in an unerupted second premolar. *ASDC J Dent Child* 1981;48:46-49.
- Giunta JL, Kaplan MA. "Caries-like" dentin radiolucency of unerupted permanent tooth from developmental defects. *J Pedod* 1981;5:249-255.
- Brooks JK. An unusual case of idiopathic internal root resorption beginning in an unerupted permanent tooth. *J Endod* 1980;12:309-310.
- Jacobs SG. Intracoronal radiolucencies in unerupted teeth of orthodontic patients: three case reports. *Aust Orthod J* 1991;12:10-12.
- Taylor NG, Gravely JF, Hume WJ. Resorption of the crown of an unerupted permanent molar. *Int J Paediatr Dent* 1991;1:89-92.
- Moskovitz M, Holan G. Pre-eruptive intracoronal radiolucent defect: a case of a nonprogressive lesion. *J Dent Child (Chic)* 2004;71:175-178.
- Singer S, Abbott PV, Booth DR. Idiopathic coronal radiolucencies in unerupted permanent teeth. Case reports. *Aust Dent J* 1991;36:32-37.
- McNamara CM, Foley T, O'Sullivan VR, et al. External resorption presenting as an intracoronal radiolucent lesion in a pre-eruptive tooth. *Oral Dis* 1997;3:199-201.