
Contralateral Full-thickness Retroangular Flap for the Reconstruction of Midfacial Through-and-through Defects Following Skin Cancer Ablation

Fu Hai WEI¹, Wei Liang CHEN², Da Ming ZHANG²

Objective: To explore the use of the contralateral full-thickness retroangular island flap for reconstructing midfacial through-and-through defects.

Methods: Full-thickness retroangular flaps raised from the contralateral infraorbital region were used to reconstruct midfacial through-and-through defects in eight patients following the resection of skin cancers. The defects ranged in size from 4.5 × 5.5 cm to 6.0 × 8.0 cm (mean 5.78 × 6.06 cm). The skin and mucosa in the full-thickness flaps ranged in size from 3.0 × 9.0 cm to 4.0 × 12.0 cm (mean 3.50 × 10.25 cm) and from 2.0 × 2.0 cm to 2.5 × 3.0 cm (mean 2.19 × 2.69 cm), respectively.

Results: All the flaps survived and no complications occurred. The patients were followed for an average of 9.0 months (range 6-13 months). The vascularity of the flaps was good and the colour and texture matches were excellent. Cosmetic and functional outcomes were satisfactory in all patients.

Conclusion: The contralateral full-thickness retroangular island flap containing the angular vessels in the pedicle is technically simple to use and is a good alternative for the reconstruction of moderate to large midfacial through-and-through defects.

Key words: retroangular flap, orbitonasolabial flap, nasolabial flap, cheek defect

The reconstruction of midfacial through-and-through defects following skin cancer ablation is challenging due to the anatomical and functional complexity of the area; variability in the thickness, colour and quality of the skin; donor-site morbidity; and the need to achieve good aesthetic results. In 2000, Iida et al¹ described a new reconstructive method in which full-thickness nasal defects were repaired with a full-thickness island flap collected from the nasolabial region, with the retrograde angular artery serving as the pedicle. In 2005, Dagle-

gorio et al² used a contralateral orbitonasolabial flap to reconstruct defects in the orbital and periorbital regions. Recently, we reported the use of retroangular flaps raised from the contralateral infraorbital region to reconstruct midfacial defects after the resection of skin cancers³. In the present study, we used contralateral full-thickness retroangular island flaps to reconstruct moderate to large midfacial through-and-through defects following the resection of skin cancer.

Materials and methods

A total of eight patients with skin cancer in the cheek and nose were treated at the Department of Stomatology, the First Hospital of Zhaoqing, Guangdong Province, P.R. China and the Department of Oral and Maxillofacial Surgery, Sun Yat-sen Memorial Hospital, Sun Yat-sen University, Guangzhou, P.R. China, between September 2009 and January 2011. The patients comprised five men and three women ranging in age from 59 to 75 years

1 Department of Stomatology, First Hospital of Zhaoqing, Guangdong Province, P.R. China.

2 Department of Oral and Maxillofacial Surgery, Sun Yat-sen Memorial Hospital, Sun Yat-sen University, Guangzhou, P.R. China.

Corresponding author: Dr Wei Liang CHEN, Department of Oral and Maxillofacial Surgery, Sun Yat-sen Memorial Hospital, Sun Yat-sen University, 107 Yan-jiang Road, 510120 Guangzhou, P.R. China. Tel: 86-20-81332429; Fax: 86-20-81332853; E-mail: drchen@vip.163.com

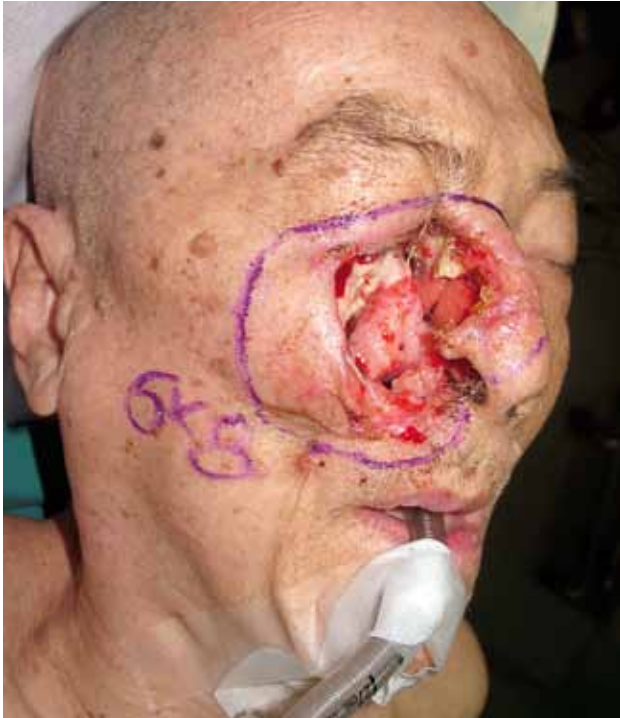

Fig 1 A 75-year-old man (case 1) with recurrent basal cell carcinoma extending from the cheek to the nose and orbital region. The patient underwent a partial resection of the maxilla and exenteration of the orbit. The incision is outlined.

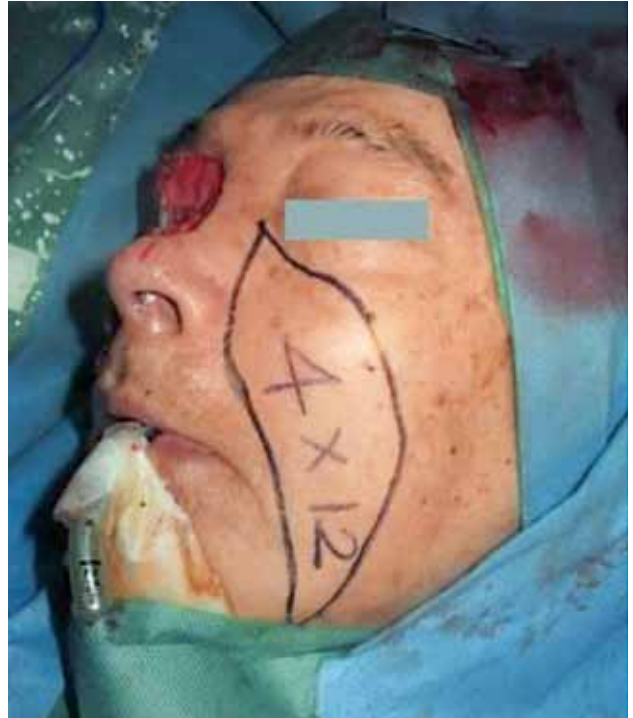

Fig 2 A retroangular island flap is outlined in the contralateral orbitonasolabial region.

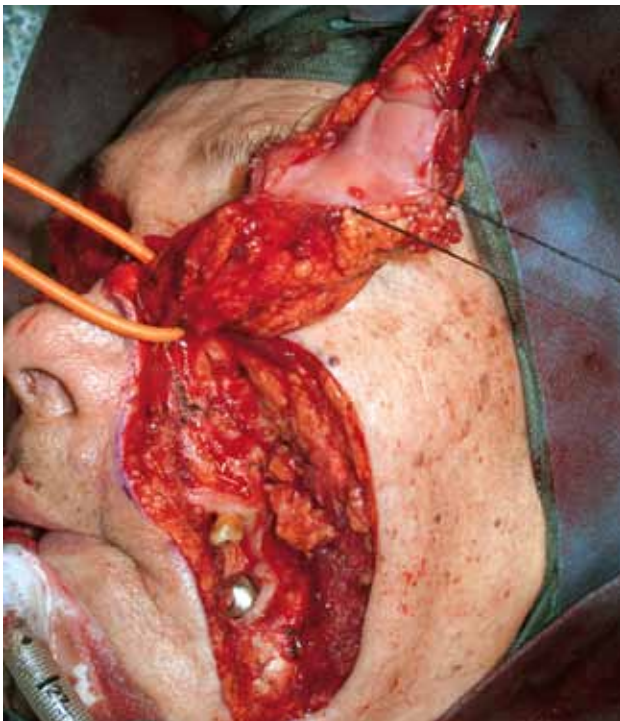


Fig 3 The skin and mucosa in the full-thickness flaps had maximum dimensions of 4.0 x 12.0 cm and 2.5 x 3.0 cm, respectively; the flap was harvested with the base at the retroangular vessels.

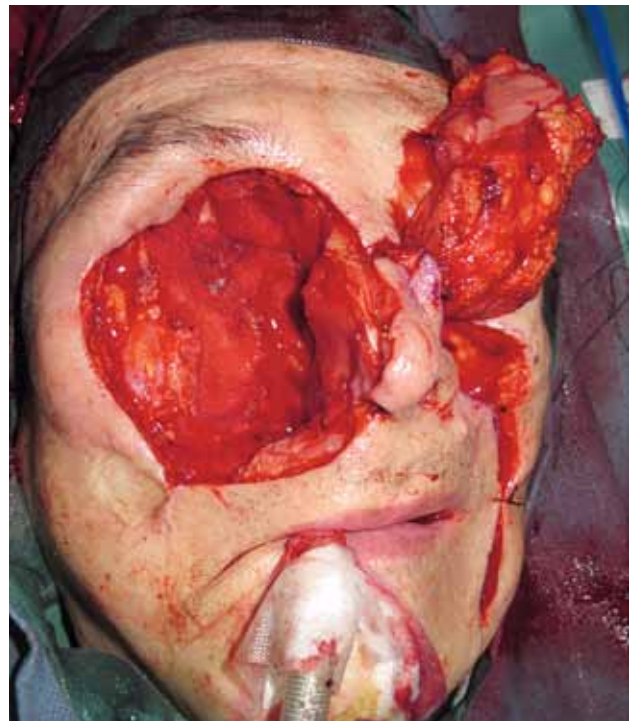


Fig 4 The lesion and the involved skin and mucosa of the mouth and maxilla were removed completely, leaving a 6.0 x 8.0 cm through-and-through midfacial defect.

(mean 69.3 years). All patients presented with malignancy; seven patients had basal cell carcinoma and one patient had malignant melanoma. Diagnoses were confirmed pathologically.

The tumours were resected with 0.5 cm lateral margins (Fig 1). Each midfacial through-and-through defect was reconstructed using a contralateral full-thickness retroangular island flap containing the angular vessels in the pedicle. The Institutional Review Board of Sun Yat-sen Hospital provided ethical approval for the study.

The defects ranged in size from 4.5×5.5 cm to 6.0×8.0 cm (mean 5.78×6.06 cm). The skin and mucosa in the full-thickness flaps ranged in size from 3.0×9.0 cm to 4.0×12.0 cm (mean, 3.50×10.25 cm) and from 2.0×2.0 cm to 2.5×3.0 cm (mean 2.19×2.69 cm), respectively. This type of flap provides both skin and mucosa for midfacial through-and-through defects. The flap donor area was closed directly.

Surgical technique

Three-dimensional computed tomographic angiography or Doppler mapping was used preoperatively to identify the facial artery and its terminal branching retroangular vessels³. The retroangular island flap was outlined in the contralateral orbitonasolabial region (Fig 2). The inner canthus served as the pivot of the flap and was used to determine the length of the flap pedicle. The skin island of the flap was shaped to fit the midfacial defect. The flap could be approximately 30% shorter than the defect was wide.

A skin incision was made to raise the island flap base on the retroangular vessels caudocephalically. At the level of the upper lip, the branch of the superior labial artery originating from the distal facial artery was exposed and ligated. The anastomosis between the angular and lateral nasal arteries was coagulated carefully with bipolar cautery. On the lateral border of the flap, somewhat inferior to the ala of the nose, the facial vein was also coagulated. Oral mucosa and buccal skin were dissected in the oral cavity, and a full-thickness retroangular island flap containing the angular vessel in the pedicle was then harvested (Fig 3). The midfacial lesions and any other involved tissue were removed completely (Fig 4). The full-thickness flap was then rotated approximately 75 to 90 degrees and provided both skin and mucosa for the midfacial through-and-through defects. The donor site was closed directly and the suture was hidden in the nasolabial fold.

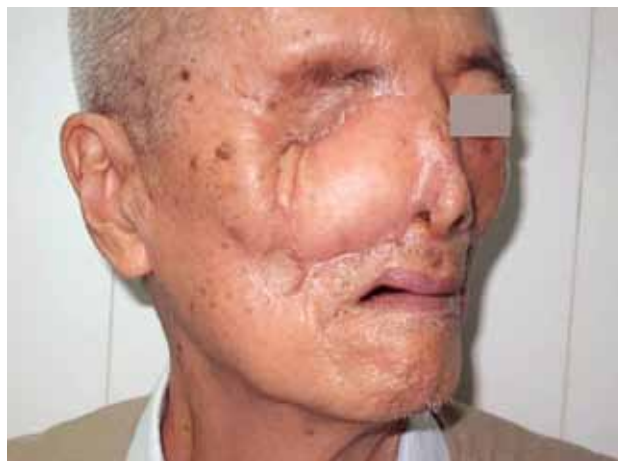

Fig 5 Postoperative photograph at 11 months after the defect was repaired.

Results

All flaps survived and no complications occurred. The patients were followed for an average of 9.0 months (range 6-13 months). The vascularity of the flaps was good and the colour and texture matches were excellent. Cosmetic and functional outcomes were satisfactory in all patients (Fig 5). The donor-site scars in the nasolabial groove were acceptable. The patients' speech and diet were restored to normal postoperatively. The patient with malignant melanoma developed local recurrence (Table 1).

Discussion

Blasius designed the first orbitonasolabial flap in 1842, and since then the flap design has been modified by many surgeons². This type of flap, called the retroangular flap, contains the angular vessels⁴. Such flaps have been used to reconstruct midfacial defects of the nose⁴⁻⁶, eyelid⁷ and cheek⁵. The retroangular flap is usually used to reconstruct small ipsilateral facial defects. Dagherio et al² used a contralateral orbitonasolabial flap to reconstruct moderately sized periorbital defects. Chen et al³ reported the use of retroangular flaps raised from the contralateral infraorbital region to reconstruct moderate to large (3.0×3.0 cm to 5.0×7.0 cm) midfacial defects in 12 patients after the resection of skin cancers.

The retroangular island flap is an axial pedicled flap nourished by reverse blood flow through the angular artery, which is the terminal branch of the facial artery⁴. In this study, skin and mucosa in the full-thickness flap, ranging in size from 3.0×9.0 cm to 4.0×12.0 cm and from 2.0×2.0 cm to 2.5×3.0 cm, respectively, could be harvested and defects ranging in size from 4.5×5.5 cm

Table 1 Patient demographics, clinical characteristics and outcomes

Case no., age (yr), sex	Location, pathology	Defect size (cm)	Full-thickness flap: skin, mucosa (cm)	Follow-up (months)	Aesthetic results	Status
1, 75, M	Right cheek and nose, R-BCC	6.0 × 8.0	4.0 × 12.0, 2.5 × 3.0	11	S	AND
2, 71, M	Left cheek, BCC	4.5 × 5.5	3.0 × 9.0, 2.0 × 3.0	8	E	AND
3, 69, F	Right cheek, R-BCC	6.0 × 6.0	4.0 × 12.0, 2.5 × 3.0	10	S	AND
4, 64, M	Left cheek, BCC	5.5 × 6.0	3.5 × 10.0, 2.0 × 2.5	7	E	AND
5, 73, F	Right cheek and nose, BCC	5.5 × 5.5	3.5 × 9.0, 2.0 × 2.5	9	S	AND
6, 59, M	Left cheek, BCC	5.0 × 5.0	3.0 × 9.0, 2.0 × 2.0	13	E	AND
7, 73, F	Left cheek, BCC	6.0 × 7.0	4.0 × 12.0, 2.5 × 3.0	8	E	AND
8, 70, M	Right cheek, MM	4.5 × 5.5	3.0 × 9.0, 2.0 × 2.5	6	S	AWD

M, male; F, female; R, recurrent; BCC, basal cell carcinoma; MM, malignant melanoma; S, satisfactory appearance; E, excellent appearance; AND, alive, no disease; AWD, alive with disease.

to 6.0 × 8.0 cm could be repaired with primary closure. All flaps survived and no complications occurred. The vascularity of the flaps was good and the colour and texture matches were excellent. Cosmetic and functional outcomes were satisfactory in all patients. Thus, the contralateral full-thickness retroangular island flap containing the angular vessels in the pedicle is technically simple to use and is a good alternative for the reconstruction of moderate to large midfacial through-and-through defects. Another advantage of this technique is that it is suitable for elderly patients.

A retroangular island flap can be elevated from the corner of the mouth up to the medial canthus; this flap has a very long reach and can be rotated approximately 75 to 90 degrees and positioned to cover defects of the cheek and nose and to reconstruct the nose without tension. To avoid facial asymmetry, the flap can be approximately 30% shorter than the width of the defect³.

The facial artery has been studied in detail. After the three main branches – the submental, inferior labial and superior labial arteries – diverge from the facial artery, the angular artery courses beneath the skin and a thin layer of muscle fibres along the nasal groove. It terminates near the medial canthus, where it creates a rich vascular plexus with the contralateral angular artery and supraorbital artery^{8,9}. This anatomical feature enables the development of a reverse-flow flap based on the angular artery.

Three types of anatomical variation occur in the branches of the facial artery: the facial artery bifurcates into the lateral nasal and superior labial arteries at the angle of the mouth, the facial artery becomes the

angular artery after the superior labial and lateral nasal arteries branch off sequentially, and the facial artery becomes the angular artery after the superior labial artery branches off¹⁰. Due to the anatomical variation in the termination of the facial artery as the angular facial artery, three-dimensional computed tomographic angiography or Doppler mapping must be used preoperatively to identify the facial artery and its terminal branching retroangular vessels³.

References

1. Iida N, Ohsumi N, Tsutsumi Y et al. The full-thickness retroangular flap. *Ann Plast Surg* 2000;45:544–549.
2. Dagregorio G, Baraer F, Darsonval V. Seven reconstructions of the orbital and periorbital region with a contralateral orbitonasolabial flap. *Br J Plast Surg* 2005;58:940–943.
3. Chen WL, Wang YY, Zhang DM et al. Use of the contralateral retroangular island flap for reconstructing midfacial defects after skin cancer ablation. *Head Neck*. 2011;33:1765–1768.
4. Fabrizio T, Savani A, Sanna M et al. The retroangular flap for nasal reconstruction. *Plast Reconstr Surg* 1996;97:431–435.
5. Ascari-Raccagni A, Baldari U. The retroangular flap used in the surgery of nasal tip defects. *Dermatol Surg* 2004;30:1131–1137.
6. Seo YJ, Hwang C, Choi S, et al. Midface reconstruction with various flaps based on the angular artery. *J Oral Maxillofac Surg* 2009;67:1226–1233.
7. Tan O, Atik B, Ergen D. The retroangular flap revisited. *Dermatol Surg* 2007;33:1343–1349.
8. Niranjan NS. An anatomical study of the facial artery. *Ann Plast Surg* 1988;21:14–22.
9. Whetzel TP, Mathes SJ. Arterial anatomy of the face: An analysis of vascular territories and perforating cutaneous vessels. *Plast Reconstr Surg* 1992;89:591–603.
10. Nakajima H, Imanishi N, Aiso S. Facial artery in the upper lip and nose: Anatomy and a clinical application. *Plast Reconstr Surg* 2002;109:855–861.