

Mineral Trioxide Aggregate Versus Calcium Hydroxide for Pulpotomy in Primary Molars

He LIU¹, Qiong ZHOU¹, Man QIN¹

Objective: To compare the effects of mineral trioxide aggregate (MTA) and calcium hydroxide (CH) for pulpotomy in primary molars.

Methods: A randomised, bilateral self-controlled clinical trial was designed to compare the clinical effect of MTA and CH in pulpotomies in primary molars in 4- to 9-year-old children. Children with two similar-sized cavities on bilateral primary molar counterparts requiring pulpotomies were included. The two contralateral molars in each patient were randomly assigned to MTA or CH treatment. Clinical and radiographic examinations were performed to evaluate the treatment results at post-treatment recall.

Results: Seventeen pairs of self-controlled contralateral teeth were available for follow-up evaluations. The success rate of MTA was 94.1% (16/17), while the success rate of CH was 64.7% (11/17). Internal root resorption was the most frequent reason for failure in the CH group. Crown discolouration was common in the MTA-treated group.

Conclusion: MTA was more successful than CH for pulpotomies in primary molar teeth, and may be a suitable replacement for CH in primary molar pulpotomies.

Key words: calcium hydroxide, internal root resorption, mineral trioxide aggregate, primary molars, pulpotomy

Pulpotomy is one of the options for pulp treatment in primary teeth. It is based on the rationale that after surgical amputation of the infected coronal pulp, the radicular pulp tissue is kept in a healthy state, and that a more natural environment is maintained for the development of the underlying successor. Literature has reported that the eruption time and orientation of permanent teeth may change when their corresponding primary teeth have undergone pulpectomy¹.

Calcium hydroxide (CH) has been used as a pulp dressing material in pulpotomy for years. The alkaline pH induced by CH activates alkaline phosphatase,

which plays an important role in dentine formation^{2,3}. Calcium hydroxide pulpotomy has been successfully used in permanent teeth. However, when applied on primary teeth, the success rates drop because of the possibility of internal resorption⁴⁻⁸.

Mineral trioxide aggregate (MTA), which has excellent physical and chemical properties, has been proposed as a potential medicament for use in pulpotomies. It is composed mainly of tricalcium silicate, dicalcium silicate, tricalcium aluminate, calcium sulphate dehydrate and bismuth oxide. It is biocompatible⁹, provides a better seal than amalgam¹⁰ and promotes hard tissue regeneration when placed in contact with dental pulp¹¹. In animal studies, a relatively complete dentine bridge formed under MTA dressing and the underneath pulp tissue remained in a more normal physiological state¹²⁻¹⁴. However, few clinical studies, especially long-term studies, have been conducted.

The purpose of this study was to compare the effects of MTA and CH pulpotomies on primary teeth, with an observing period of 10 to 56 months.

¹ Department of Pediatric Dentistry, Peking University School and Hospital of Stomatology, Beijing, P.R. China.

Corresponding author: Dr Man QIN, Department of Pediatric Dentistry, Peking University School and Hospital of Stomatology, #22 Zhongguancun Nandajie, Haidian District, Beijing 100081, P.R. China. Tel: 86-10-82195361; Fax: 86-10-62173402; E-mail: qinman@pkuss.bjmu.edu.cn

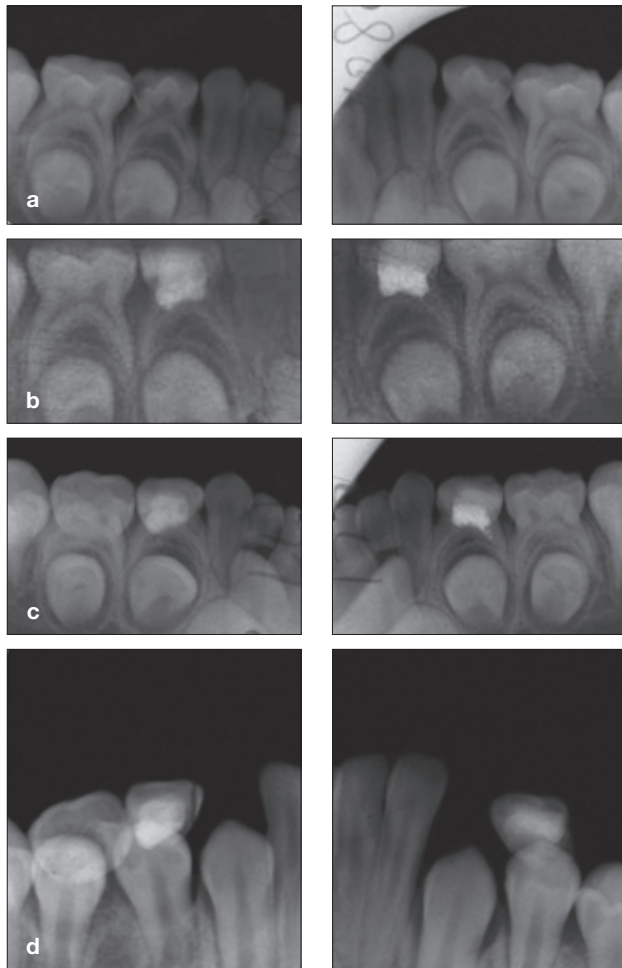


Fig 1 MTA (left column) and CH (right column) pulpotomies were performed on contralateral first primary molars. Both teeth showed success after 54 months. Radiographs taken: a) before operation; b) immediately after pulpotomy; c) 11 months after pulpotomy; and d) 54 months after pulpotomy. At 54 months the roots of the primary first molars were resorbed completely and the successor permanent teeth were erupting.

Materials and methods

This study was conducted at the Department of Pediatric Dentistry, Peking University School and Hospital of Stomatology. Eighteen children aged 4 to 9 years were included in the study, with the consent of their parents.

Each child had at least two similar-sized cavities on bilateral primary molar counterparts requiring pulpotomies based on clinical and radiographic examinations. The inclusion criteria were: (1) 4 to 9 years old; (2) no systemic diseases; (3) no spontaneous pain; (4) no discomfort at percussion, no pathological mobility and no swelling or fistula; (5) no periapical or furcal radiolucency at radiographic examination, no

pathological root resorption of the primary teeth and an intact surrounding of the permanent successor; (6) pulp exposure after complete removal of decay; (7) no excessive bleeding from the root canal after coronal pulp amputation.

A randomised, bilateral self-controlled clinical trial was designed to compare the clinical effect of MTA and CH pulpotomies in primary molars in these children. The two contralateral molars in each patient were randomly assigned to MTA (ProRoot[®] MTA, Dentsply, York, PA, USA) or CH (50% calcium hydroxide mixed with 50% iodoform; with 2 g tetracaine and 0.5 g sodium benzoate in 100 ml distilled water) treatment. The selected teeth were treated by a conventional pulpotomy technique under local anaesthesia. After caries removal and pulp chamber exposure, the coronal pulp was amputated with a round bur. Haemorrhage was controlled by placing sterile, saline-wetted cotton pellets on the radicular pulp stumps under slight pressure. MTA or CH agent was conventionally mixed and placed on the pulp stumps. Vitrebond[™] (3M ESPE, St. Paul, MN, USA) GIC cement was placed over the pulp capping agent and conventional resin composite restoration was performed.

Children were recalled for clinical and radiographic examinations at 6-month intervals. The treatment was judged as successful if the teeth met with the following criteria: (1) at clinical examination, the teeth showed no symptoms of pain, no swelling or fistula, no tenderness to percussion and no pathological mobility, and (2) at radiographic examination, the teeth showed no periapical or interradicular radiolucency or pathological root resorption.

Results

In total, 18 children with 40 primary teeth (20 pairs of contralateral self-controlled teeth) were included in the present study. Among them, 15 children (with 17 pairs of contralateral self-controlled teeth) were available for follow-up evaluations. The follow-up period was 10 to 56 months, with six children followed up for 43, 46, 50, 54, 54 and 56 months, respectively.

Among the 17 pairs of controlled teeth, 11 pairs were clinically and radiographically successful for both MTA and CH pulpotomy during the follow-up appointments (Fig 1 and Fig 2). One pair showed failure for both MTA and CH pulpotomy, and five pairs showed success for the MTA treatment but failure of the CH treatment. Therefore, the success rate of MTA was 94.1% (16/17), while the success rate of CH was 64.7% (11/17).

In the CH pulpotomy group, the six failure cases all showed internal root resorption (Fig 3), which was

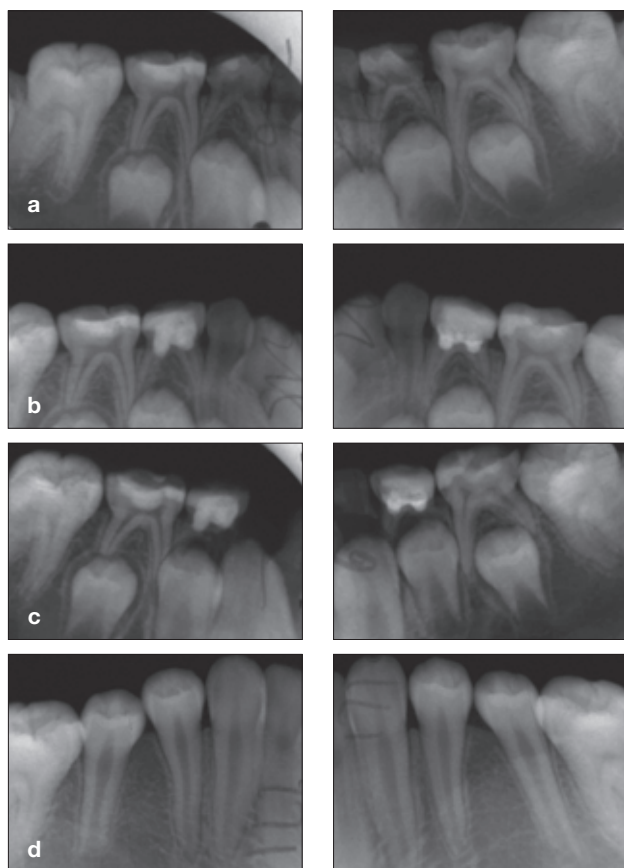


Fig 2 MTA (left column) and CH (right column) pulpotomies were performed on contralateral first primary molars. Both teeth showed success after 56 months. Radiographs taken: a) before operation; b) immediately after pulpotomy; c) 13 months after pulpotomy; and d) 56 months after pulpotomy. At 13 months the successor permanent teeth had developed normally and the roots of the primary first molars were physiologically resorbed. At 56 months the successor permanent teeth were already erupted and were in good alignment clinically.

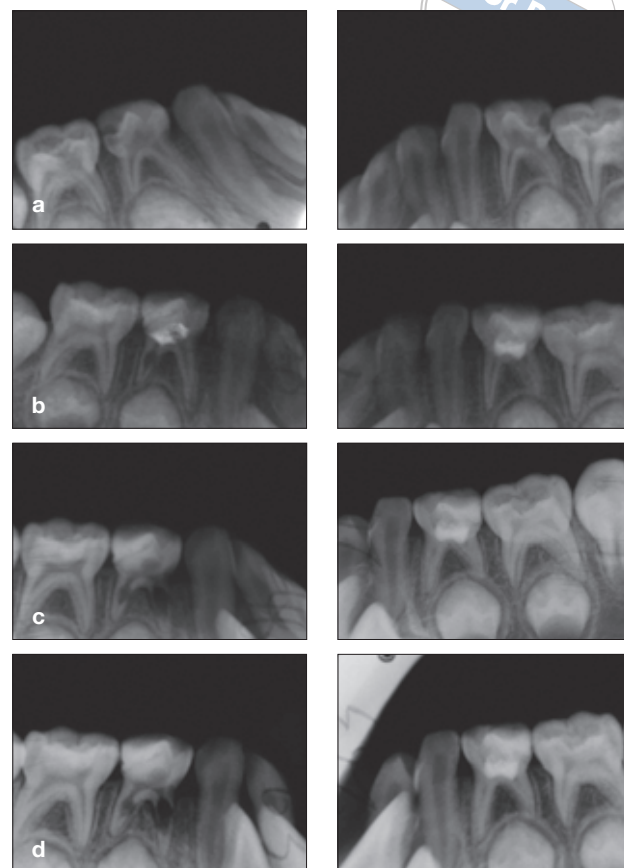


Fig 3 CH pulpotomy (left column) was performed on the right mandibular first molar and MTA pulpotomy (right column) on the left mandibular first molar. The MTA treatment showed success after 19 months, while the CH treatment failed. Radiographs taken: a) before operation; b) 5 months after pulpotomy; c) 15 months after pulpotomy; and d) 19 months after pulpotomy. At 5 months the CH-treated tooth showed internal root resorption while the MTA-treated tooth was normal. The internal root resorption in the CH-treated tooth enlarged with no periapical radiolucency, while the MTA-treated tooth remained normal.

observed at 5, 6, 9, 11, 17 and 22 months after the pulpotomy, respectively. For the one failure case of MTA pulpotomy, periapical radiolucency appeared at 8 months postoperatively.

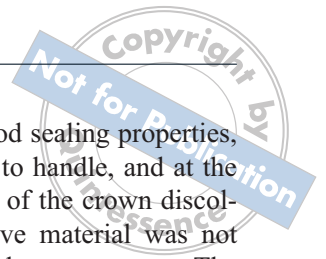
In the MTA group, crown discolouration occurred in 11 out of the 17 cases. The crowns turned dark grey (Fig 4).

Discussion

This study evaluated the clinical and radiographic success and failure rates of pulpotomies using CH or MTA in primary molar teeth. The results showed that MTA was more successful than CH for pulpotomies in primary

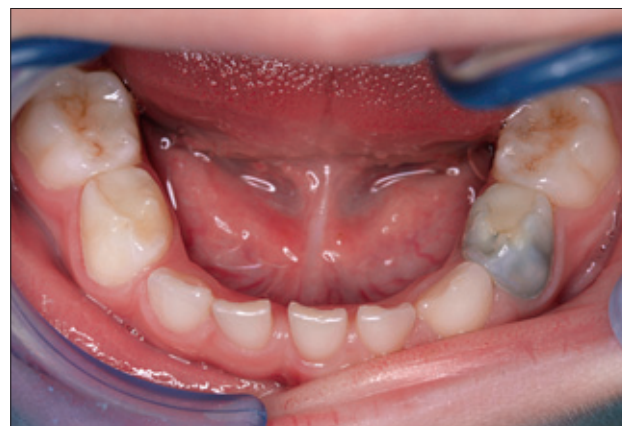

Fig 4 Discolouration of MTA-treated tooth.



molar teeth. Only one MTA-treated tooth failed, while six of the CH-treated teeth failed. Internal resorption was a common radiographic finding in the CH-treated teeth that failed during the observation period.

Studies on gnotobiotic rats have shown that when traumatically exposed teeth in germ-free animals were dressed, healing occurred irrespective of the capping material used¹⁵. This implies that under normal conditions the healing influence of CH is due to its antibacterial activity, rather than any effect it may exert on mineralisation. The antibacterial and antifungal properties of CH and MTA have been extensively evaluated¹⁵⁻²⁴. Nakajo et al²⁵ found that most bacteria could not tolerate pH higher than 10. Both MTA and CH have a very high pH value. The pH value of MTA is 10.2 after mixing and rises to 12.5 at 3 h²⁶. The bactericidal properties are thought to be directly related to pH, and are directly proportional to the ability of CH and MTA to diffuse from the set material. Compared with amalgam, super-EBA and ZOE, MTA has a superior bactericidal effect on five out of nine facultative anaerobes frequently detected in contaminated root canals without cytotoxicity, which might be related to its high pH value^{18,23}.

Clinical success rates ranging from 31% to 100% have been reported for CH as a pulpotomy dressing⁴⁻⁸. In the present study, 6 out of 17 (35.5%) CH-treated teeth failed because of internal root resorption. Failure has been reported frequently in pulpotomy of primary teeth using CH as pulp-capping medicament, which mostly manifested as extensive pulp inflammation or internal root resorption. In Moretti's 24-month study, 64% of the teeth presented clinical and radiographic failures detected throughout the follow-up period in the CH group and internal resorption was a frequent radiographic finding. Meanwhile 100% of the available teeth in the MTA group were clinically and radiographically successful at all follow-up appointments²⁷. The aetiology of the internal resorption is thought to be chronic pulpitis^{28,29}. In the present study, although internal resorption was categorised as a radiographic failure, the teeth presenting this pathology were not treated immediately, but were left for follow-up observation. This approach was adopted if the teeth were asymptomatic and did not show any sign of clinical failure.

Healing of the dental pulp is not exclusively dependent on the supposed stimulatory effect of a particular type of medicament, but is directly related to the capacity of both the dressing and definitive restorative material to provide a biological seal against immediate and long-term microleakage along the entire restoration interface^{8,30,31}. In this study, resin composite was used

to restore the teeth, which has good sealing properties, good wear resistance and is easy to handle, and at the same time allows the observation of the crown discolouration. Therefore, the restorative material was not a discriminating factor between the two groups. The results corroborate the findings of other reports, which demonstrated the superiority of MTA in comparison with CH^{31,32}.

In present study, the dentine bridge was not recorded or considered as a sign of success for pulpotomy because the concept of dentine bridging is controversial. The presence of a bridge can be viewed as a healing response or as a pulp reaction to irritation^{11,31}. Waterhouse et al²⁹ suggested that reactionary dentine formation is a sign or consequence of attempted repair processes within the pulp tissue. Nevertheless, after an initial healing of the insult by the pulp tissue, the reactive process may fail, leading to clinical failure. Furthermore, the formation of a bridge does not mean that the pulp will be sealed completely from the environment: an animal study observed that 89% of dentine bridges formed following capping procedures with CH had tunnel defects, and that 41% of the dentine bridges were associated with recurring pulp inflammation^{31,33,34}.

Despite its many advantages – biocompatibility, sealing ability and immense potential for regeneration – MTA has some drawbacks, such as a tendency for discolouration^{26,27}. In the present study, the crown discolouration occurred in 11 out of 17 cases in the MTA group, which affected tooth aesthetics to some extent. Other than that, the better results for MTA than CH in this study indicate that MTA shows promise for use as a pulp capping medicament for pulpotomies in primary molars.

Conclusion

MTA was more successful than CH for pulpotomies in primary molar teeth as only one of the MTA-treated teeth showed radiographic pathology, whereas six of the CH-treated teeth showed radiographic failure through internal resorption. Despite its tendency to discolour, MTA is a suitable replacement for CH in primary molar pulpotomies.

References

1. Coll JA, Sadrian R. Predicting pulpectomy success and its relationship to exfoliation and succedaneous dentition. *Pediatr Dent* 1996;18:57-63.
2. Mitchell DF, Shankwalker GB. Osteogenic potential of calcium hydroxide and other materials in soft tissue and bone wounds. *J Dent Res* 1958;37:1157-1163.

3. Tronstad L, Andreassen JO, Hasselgren G et al. pH changes in dental tissues after root canal filling with calcium hydroxide. *J Endod* 1981;7:17–21.
4. Magnusson B. Therapeutic pulpotomy in primary molars – clinical and histological follow-up. I. Calcium hydroxide paste as wound dressing. *Odontol Revy* 1970;21:415–431.
5. Schröder U. A 2-year follow-up of primary molars, pulpotomized with a gentle technique and capped with calcium hydroxide. *Scand J Dent Res* 1978;86:273–278.
6. Waterhouse PJ. Formocresol and alternative primary molar pulpotomy medicaments: A review. *Endod Dent Traumatol* 1995;11:157–162.
7. Waterhouse PJ, Nunn JH, Withworth JM. An investigation of the relative efficacy of Buckley's Formocresol and calcium hydroxide in primary molar vital pulp therapy. *Br Dent J* 2000;188:32–36.
8. Percinoto C, de Castro AM, Pinto LM. Clinical and radiographic evaluation of pulpotomies employing calcium hydroxide and trioxide mineral aggregate. *Gen Dent* 2006;54:258–261.
9. Torabinejad M, Ford TR, Abedi HR et al. Tissue reaction to implanted root-end filling materials in the tibia and mandible of guinea pigs. *J Endod* 1998;24:468–471.
10. Torabinejad M, Higa RK, McKendry DJ et al. Dye leakage of four root end filling materials: Effects of blood contamination. *J Endod* 1994;20:159–163.
11. Dominguez MS, Witherspoon DE, Gutmann JL et al. Histological and scanning electron microscopy assessment of various vital pulp-therapy materials. *J Endod* 2003;29:324–333.
12. Ford TR, Torabinejad M, Abedi HR et al. Using mineral trioxide aggregate as a pulp-capping material. *J Am Dent Assoc* 1996;127:1491–1494.
13. Faraco IM Jr, Holland R. Response of the pulp of dogs to capping with mineral trioxide aggregate or a calcium hydroxide cement. *Dent Traumatol* 2001;17:163–166.
14. Tziafas D, Pantelidou O, Alvanou A et al. The dentinogenic effect of mineral trioxide aggregate (MTA) in short-term capping experiments. *Int Endod J* 2002;35:245–254.
15. Watts A, Paterson RC. Bacterial contamination as a factor influencing the toxicity of materials to the exposed dental pulp. *Oral Surg Oral Med Oral Pathol* 1987;64:466–474.
16. Holt DM, Watts JD, Beeson TJ et al. The anti-microbial effect against *Enterococcus faecalis* and the compressive strength of two types of mineral trioxide aggregate mixed with sterile water or 2% chlorhexidine liquid. *J Endod* 2007;33:844–847.
17. Estrela C, Bammann LL, Estrela CR et al. Antimicrobial and chemical study of MTA, Portland cement, calcium hydroxide paste, Sealapex and Dycal. *Braz Dent J* 2000;11:3–9.
18. Torabinejad M, Hong CU, Pitt Ford TR et al. Antibacterial effects of some root end filling materials. *J Endod* 1995;21:403–406.
19. Al-Nazhan S, Al-Judai A. Evaluation of antifungal activity of mineral trioxide aggregate. *J Endod* 2003;29:826–827.
20. Zhang H, Pappen FG, Haapasalo M. Dentin enhances the antibacterial effect of mineral trioxide aggregate and bioaggregate. *J Endod* 2009;35:221–224.
21. Cox CF, Bergenholtz G, Fitzgerald M et al. Capping of the dental pulp mechanically exposed to the oral microflora – a 5-week observation of wound healing in the monkey. *J Oral Pathol* 1982;11:327–339.
22. Fisher FJ. The effect of calcium hydroxide-water paste on microorganisms in carious dentine. *Br Dent J* 1972;133:19–21.
23. Fisher FJ, McCabe JF. Calcium hydroxide base materials. An investigation into the relationship between chemical structure and antibacterial properties. *Br Dent J* 1978;144:341–344.
24. King JB Jr, Crawford JJ, Lindahl RL. Indirect pulp capping: A bacteriologic study of deep carious dentine in human teeth. *Oral Surg Oral Med Oral Pathol* 1965;20:663–669.
25. Nakajo K, Nakazawa F, Iwaku M et al. Alkali-resistant bacteria in root canal systems. *Oral Microbiol Immunol* 2004;19:390–394.
26. Torabinejad M, Hong CU, McDonald F et al. Physical and chemical properties of a new root-end filling material. *J Endod* 1995;21:349–353.
27. Moretti AB, Sakai VT, Oliveira TM et al. The effectiveness of mineral trioxide aggregate, calcium hydroxide and formocresol for pulpotomies in primary teeth. *Int Endod J* 2008;41:547–555.
28. Foreman PC, Barnes IE. Review of calcium hydroxide. *Int Endod J* 1990;23:283–297.
29. Waterhouse PJ, Nunn JH, Withworth JM et al. Primary molar pulp therapy – histological evaluation of failure. *Int J Paediatr Dent* 2000;10:313–321.
30. Peng L, Ye L, Tan H et al. Evaluation of the formocresol versus mineral trioxide aggregate primary molar pulpotomy: A meta-analysis. *Oral Surg Oral Med Oral Pathol Oral Radiol Endod* 2006;102:e40–44.
31. Chacko V, Kurikose S. Human pulpal response to mineral trioxide aggregate (MTA): A histologic study. *J Clin Pediatr Dent* 2006;30:203–209.
32. Aeinehchi M, Eslami B, Ghanbari M et al. Mineral trioxide aggregate (MTA) and calcium hydroxide as pulp-capping agents in human teeth: A preliminary report. *Int Endod J* 2003;36:225–231.
33. Schuur AH, Gruythuysen RJ, Wesselink PR. Pulp capping with adhesive resin-based composite vs. calcium hydroxide: A review. *Endod Dent Traumatol* 2000;16:240–250.
34. Cox CF, Sübay RK, Ostro E et al. Tunnel defects in dentin bridges: their formation following direct pulp capping. *Oper Dent* 1996;21:4–11.