

Hyperplastic Dental Follicle – Review of Literature and Report of Two Cases in One Family

Chun Xiao SUN¹, Craig RIRIE¹, Jeffrey M HENKIN¹

Hyperplastic dental follicle is an extremely rare lesion. The practitioner should be able to differentiate it from a dentigerous cyst. The present article will review related literature and report on two cases in one family. A 12-year-old white female and her 15-year-old brother were referred for exposure of unerupted canines. No systemic diseases or syndromes were present. Intra-oral examinations were unremarkable, except for the absence of all eight canines. Radiographic examinations revealed impacted canines with each unerupted tooth surrounded by a well-demarcated radiolucency, which passed beyond the cemento-enamel junction. The teeth were surgically exposed and tissue specimens surrounding the unerupted teeth were analysed histologically. Histology revealed fibrous connective tissue with areas demonstrating some ground substance and multiple odontogenic epithelial rests. Some surfaces were partially lined by reduced enamel epithelium. A diagnosis of hyperplastic dental follicle was made. Sometimes, it is difficult to differentiate hyperplastic dental follicle from odontogenic fibroma, both simple and central forms. A correct diagnosis should be based on clinical, radiographic and histological findings.

Key words: hyperplastic dental follicle, unerupted canine

Hyperplastic dental follicle or peri-follicle fibrosis, is an unusual lesion often confused with odontogenic fibroma^{1,2}. Gardner was the first one who attempted to clarify these similar lesions¹. He pointed out that three different lesions may resemble each other. The first one is hyperplastic dental follicle, which is mainly composed of fibrous connective tissue and wavy collagen fibres. It may contain strands and rests of odontogenic epithelium. Calcified materials may be present in the connective tissue, which is then called calcifying hyperplastic dental follicle, and was first described by Sandler et al².

The second form of the lesion has been called simple odontogenic fibroma. This lesion resembles hyperplastic dental follicle histologically, but differs in its size and location. The simple odontogenic fibroma is usually much larger than hyperplastic dental follicle, and is invariably associated with crowns of unerupted teeth, which is not always the case with odontogenic fibroma. The third lesion has been named central odontogenic fibroma (WHO type). This lesion has some unique histological features such as dysplastic dentin, cementum-like calcified tissues and marked epithelial proliferation. The last two lesions are considered true neoplasms, whereas the hyperplastic dental follicle is considered a hamartomatous lesion.

Multiple hyperplastic dental follicles is an extremely rare condition. To date, there are only six cases reported in the literature (Table 1)²⁻⁶. None of these reported any symptoms, and they mainly affect unerupted posterior teeth, which accounts for 30 out of 36 teeth involved. All

¹ Department of Periodontics, Loma Linda University School of Dentistry, Loma Linda, CA, USA.

Corresponding author: Dr Jeffrey M. Henkin, Advanced Education Program in Periodontics and Implant Surgery, Loma Linda University School of Dentistry, 24860 Taylor St., Loma Linda, CA 92354, USA. Tel: 909-558-4610; Fax: 909-558-4801. E-mail: jhenkin@llu.edu

Table 1 Reported cases of multiple hyperplastic dental follicles.

Authors	Patients	Teeth affected	Defective affected teeth	Calcification
Sun, et al (current report)	15-year-old white male	6, 11, 22, 27	Not mentioned	No
	12-year-old white female	6, 11, 22, 27		
Walker, et al (reference 6)*	6-year-old female	T	Not mentioned	Foci of irregular calcification
Gomez, et al (reference 4)	15-year-old male	1, 2, 5, 6, 7, 11, 12, 15, 22, 27, 32	Unremarkable	Type A and B calcification in fibrous soft tissue and dystrophic calcification in the pulp tissue and dentine matrix
Gardner, et al (reference 5)	26-year-old white male	17, 18	Not mentioned	Type A calcification dominant
	40-year-old male	7 teeth		
Lukinmaa, et al (reference 3)	24-year-old male	18, 20	Hypoplastic enamel and defective crowns and roots	Basophilic, concentric, calcified bodies, type A calcification
Sandler, et al (reference 2)	15-year-old black male	1, 2, 13, 15, 16, 17, 18, 20, 21, 28, 29, 31, 32	Unremarkable	Abundant calcified materials in the whorled areas of the connective tissue and in the hyalinised tissue surrounding the odontogenic epithelium

* The diagnosis was hyperplastic dental follicle with an incipient adenomatoid odontogenic tumour

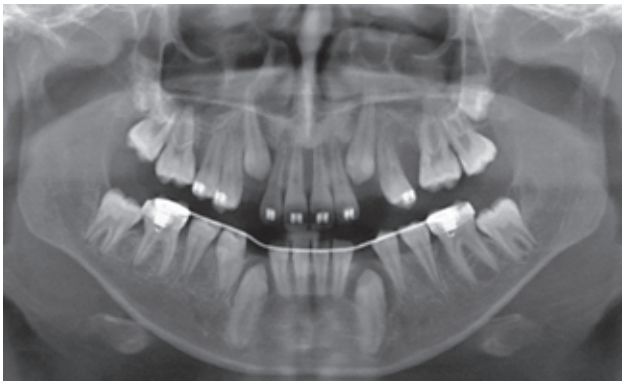


Fig 1 Panoramic radiographs of the 12-year-old female patient 6 months after tooth 13 extraction. Radiolucency around each unerupted canine was well demarcated.

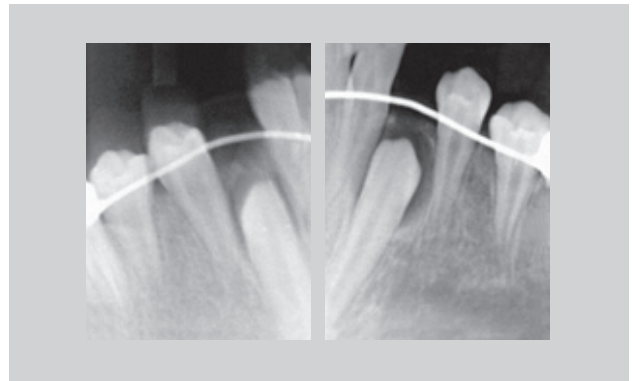


Fig 2 Radiographs showed radiolucencies passed beyond the cemento-enamel junction (CEJ). Periapical radiographs of teeth 22 (right) and 27 (left) are shown. Radiolucencies passed beyond the CEJ and no obvious resorption was noticed on adjacent teeth.

of these cases presented with calcification. In the present report, the authors present two cases; each has four unerupted canines associated with non-calcified hyperplastic dental follicles, and occur in the same family.

Case reports

In January 2009, a 12-year-old Caucasian female was referred to the Department of Periodontics, Loma Linda University School of Dentistry for exposure of unerupted teeth 6, 11, 22 and 27. The patient had unerupted tooth 13 extracted by an oral surgeon 6 months prior to the present consultation. There were no associated systemic diseases or syndromes present. Intraoral examination revealed that teeth 6, 11, 22 and 27 were not clinically present, and the patient was undergoing orthodontic treatment. Swelling on the buccal sides of teeth 22 and 27, depressible on palpation, were detected. A panoramic radiograph showed a unilocular, well-circumscribed radiolucency around the crowns of each impacted tooth (Fig 1). Teeth 1 and 16 were still forming while teeth 17 and 32 appeared to be congenitally missing. Periapical radiographs (Fig 2) and cone beam 3-D images (data not shown) showed that the radiolucencies were beyond the cemento-enamel junction.

Impacted teeth (6, 11, 22 and 27) were surgically exposed via a closed flap technique to preserve keratinised tissue, and abundant dense fibrotic tissues were found surrounding the impacted teeth, extending into the areas of the roots (Fig 3). The tissues around the impacted cuspids were collected and sent to a private laboratory for pathological analysis. Under light microscopy, the pathologist found considerable ground substance and multiple odontogenic epithelial rests, with some exhibiting juxta-epithelial hyalinisation. The histological diagnosis was hyperplastic dental follicles (peri-follicular fibrosis) without calcification (Fig 4).

Three months later, the patient's 15-year-old brother was referred to the department of periodontics for the same reason. This patient had almost identical clinical findings as his younger sister, except that all of his third molars were forming. Following his surgery, the pathological diagnosis was also reported as hyperplastic dental follicle (Fig 5).

Discussion

The most frequently impacted teeth are mandibular third molars, followed by maxillary canines, mandibular canines, premolars and incisors. The incidence of maxillary canine impaction ranges from 1 to 3%, and palatal impaction is more often observed than labial impaction

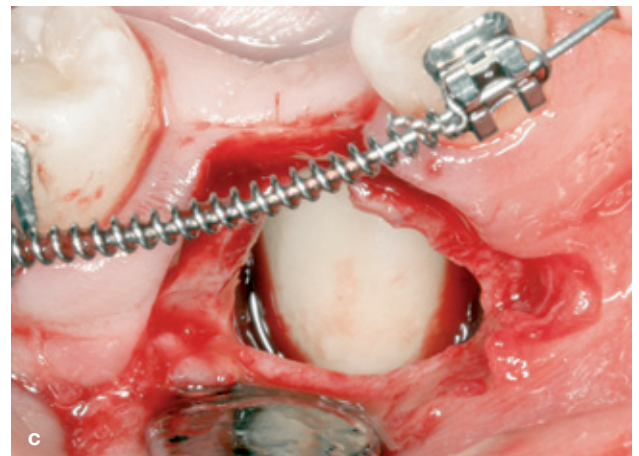
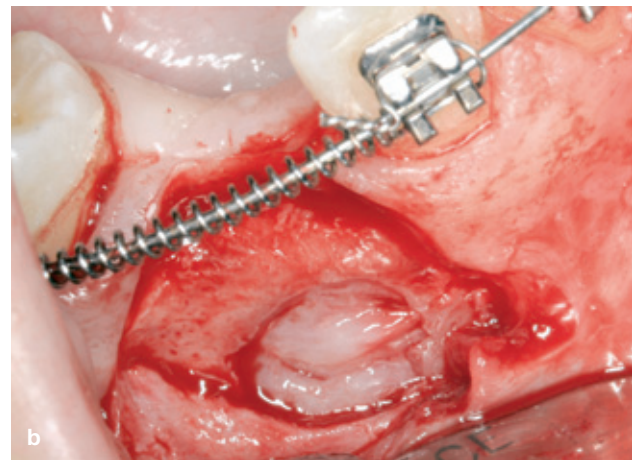
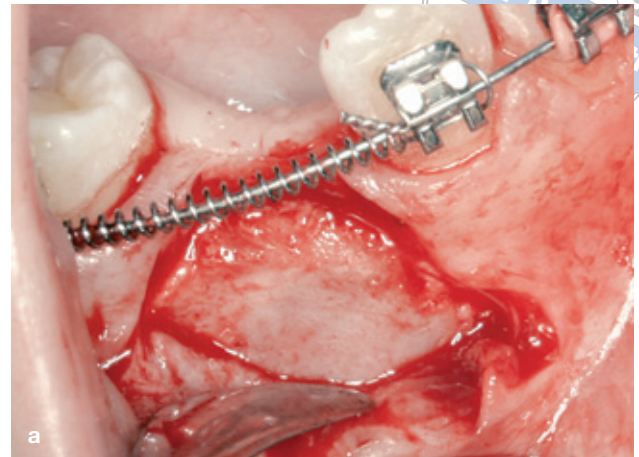
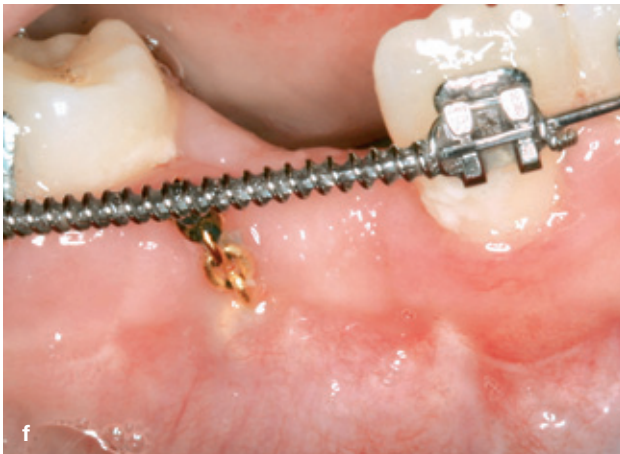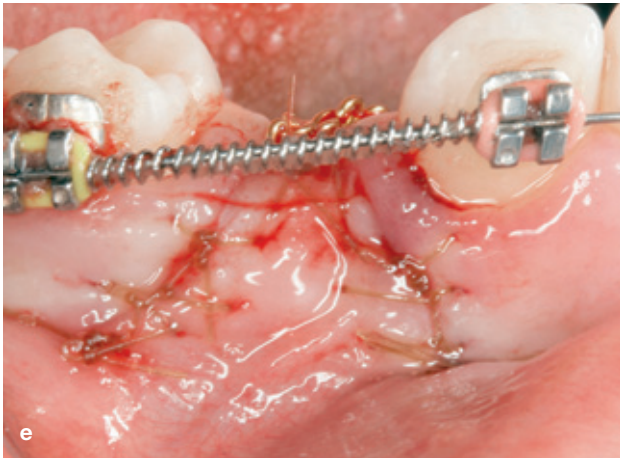
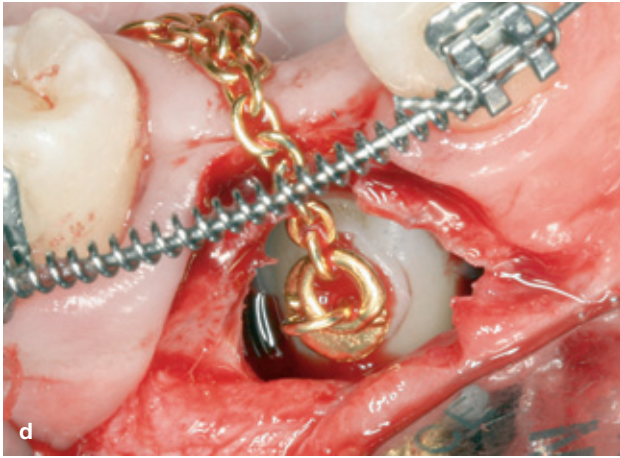


Fig 3 Exposure of impacted tooth 27. A closed flap technique was used: flap was elevated (a), outer layer of bone was removed and hyperplastic dental follicle was seen surrounding the impacted tooth (b), surrounding tissue was removed and tooth exposed (c), a gold chain was bonded onto exposed tooth surface (d), flap closed and 1 week postoperative photo (e and f, respectively).



(the ratio is approximately 2:1 to 6.6:1.)^{7,8}. The aetiology of tooth impaction is still not very clear. Possible primary causes are the rate of root resorption of deciduous teeth, trauma of the deciduous tooth bud, disturbances in tooth eruption sequence, availability of space in the arch, rotation of tooth buds, premature root closure and canine eruption into the cleft area in persons with cleft palate⁹. The proposed secondary causes are abnormal muscle pressure, febrile disease, endocrine disturbances and vitamin D deficiency⁹.

The normal pericoronal radiolucency is considered to be in the range of 2 to 3 mm¹⁰, and there is no definitive explanation of the mechanism causing hyperplastic dental follicle. Kim et al reported that the expression of several matrix metalloproteinases is down-regulated in hyperplastic dental follicles; moreover, several collagen genes are up-regulated¹¹. Previous reports have described only male patients (Table 1). The present report is the first case report involving permanent teeth in a female patient. This is also the first report of hyperplastic dental follicle involved in only canines. To the authors' knowledge, this report is also the first one to report two cases in siblings, which suggests that the condition may have a genetic predilection.

Tooth impaction caused by hyperplastic dental follicle may be associated with defective tooth formation³, and it also may be associated with other symptoms, such as amelogenesis imperfecta, rough hypoplastic type and gingival hyperplasia¹². It is very important for dentists to recognise these possible associated lesions.

Hyperplastic dental follicle may involve just one tooth or may be present in multiple teeth. Sometimes, it is difficult to differentiate hyperplastic dental follicle from odontogenic tumours, especially when calcification is present. Calcification was estimated to be present in one-third of dental follicles^{13,14}. The final diagnosis must consider the clinical, radiographic and histological features of the lesion.

Acknowledgements

The authors thank Dr Gretchen Folk, an oral pathologist, Scripps Oral Pathology Service, San Diego, CA, for providing the photomicrographs. The authors report no conflict of interest related to the present case report.

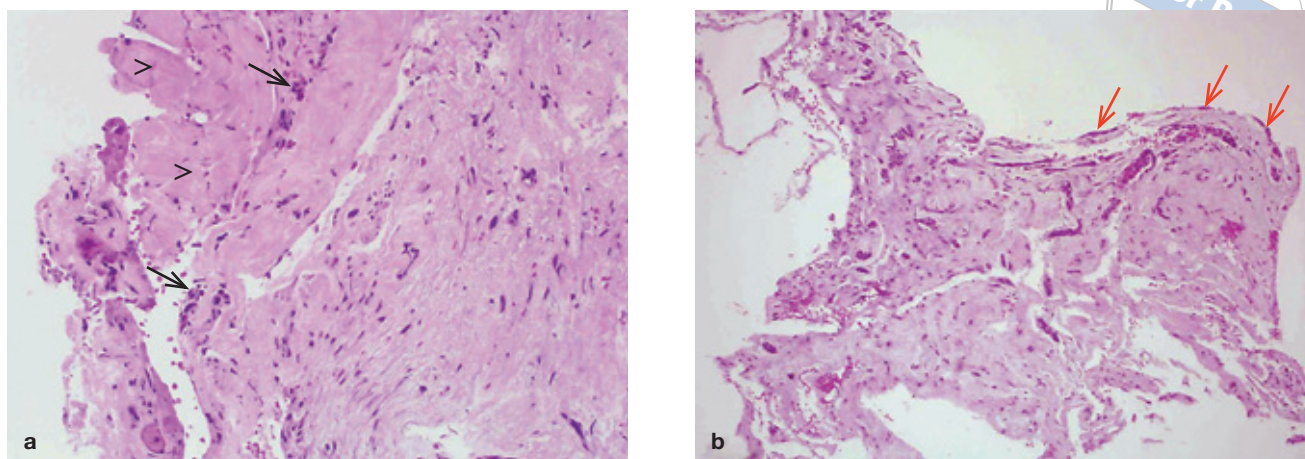


Fig 4 Histological observation with hematoxylin and eosin (H&E) staining. Abundant fibrous collagen tissues interspersed with some ground substances (arrowheads in a), and odontogenic epithelial rests (arrows in a). Some surfaces were partially lined by reduced enamel epithelium (red arrows in b). No calcification was found in either section. Original magnification $\times 20$.

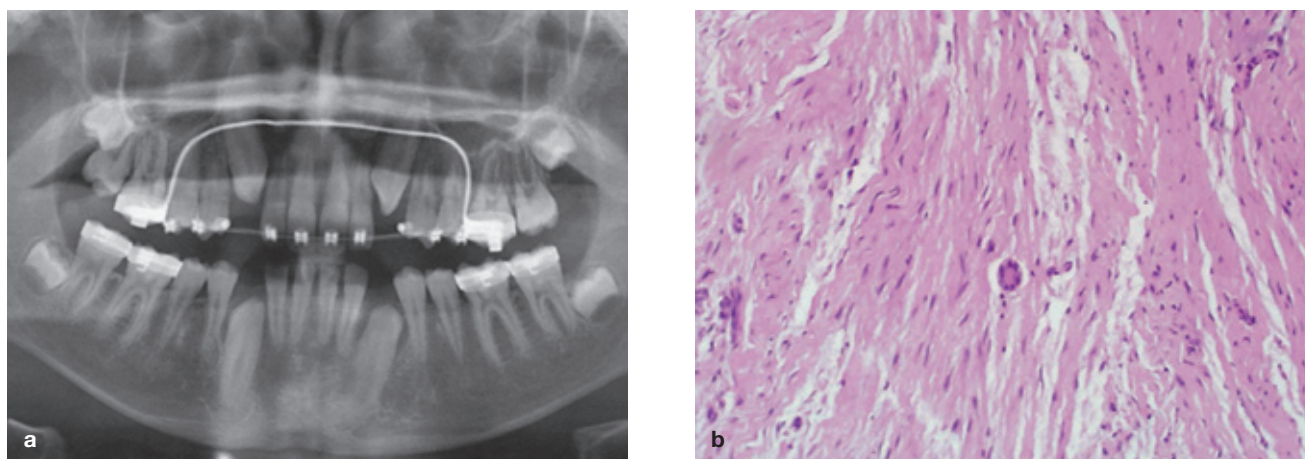


Fig 5 The radiographs and histology of the 15-year-old male patient. This patient had almost identical lesions as his sister described in Figures 1 to 3. Panoramic radiograph (a), 1 year after extraction of deciduous teeth in impacted canine positions. Histology (b) with H&E staining at magnification $\times 20$.

References

- Gardner DG. The central odontogenic fibroma: an attempt at clarification. *Oral Surg Oral Med Oral Pathol* 1980;54:425-432.
- Sandler HJ, Nersasian RR, Cataldo E, Pochebit S, Dayal Y. Multiple dental follicles with odontogenic fibroma-like changes (WHO type). *Oral Surg Oral Med Oral Pathol* 1988;66:78-84.
- Lukinmaa PL, Hietanen J, Anttinen J, Ahonen P. Contiguous enlarged dental follicles with histologic features resembling the WHO type of odontogenic fibroma. *Oral Surg Oral Med Oral Pathol* 1990;70:313-317.
- Gomez RS, Silva EC, Silva-Filho EC, Castro WH. Multiple calcifying hyperplastic dental follicles. *J Oral Pathol Med* 1998;27:333-334.
- Gardner DG, Radden B. Multiple calcifying hyperplastic dental follicles. *Oral Surg Oral Med Oral Pathol Oral Radiol Endod* 1995;79:603-606.
- Walker LM, Wood AJ, McDonald A, Carpenter W. Unerupted mandibular second primary molar with an unusual histopathological finding: a case report. *J Dent Child* 2004;71:77-79.
- Grover PS, Lorton L. The incidence of unerupted permanent teeth and related clinical cases. *Oral Surg Oral Med Oral Pathol* 1985;59:420-425.
- Jacoby H. The etiology of maxillary canine impactions. *Am J Orthod* 1983;84:125-132.
- Bishara SE, Kommer DD, McNeil MH, Montagano LN, Oesterle LJ, Youngquist HW. Management of impacted canines. *Am J Orthod* 1976;69:371-387.
- Mesgarzadeh AH, Esmailzadeh H, Abdolrahimi M, Shahamfar M. Pathosis associated with radiographically normal follicular tissues in third molar impactions: a clinicopathological study. *Indian J Dent Res* 2008;19:208-212.
- Kim SG, Kim MH, Chae CH, Jung YK, Choi JY. Downregulation of matrix metalloproteinases in hyperplastic dental follicles results in abnormal tooth eruption. *BMB Rep* 2008;41:322-327.
- Roquebert D, Champsaur A, Gil del Real P, Prasad H, Rohrer MD, Pintado M et al. Amelogenesis imperfecta, rough hypoplastic type, dental follicular hamartomas and gingival hyperplasia: report of a case from Central America and review of the literature. *Oral Surg Oral Med Oral Pathol Oral Radiol Endod* 2008;106:92-98.
- Kim J, Ellis GL. Dental follicular tissue: misinterpretation as odontogenic tumors. *J Oral Maxillofac Surg* 1993;51:762-767.
- Suarez PA, Batsakis JG, El-Naggar AK. Don't confuse dental soft tissues with odontogenic tumors. *Ann Otol Rhinol Laryngol* 1996;105:490-494.