

## Congenital External Fistula of the Accessory Parotid Gland: a Case Report

Jin Quan HE<sup>1</sup>, Lei ZHANG<sup>1</sup>, Yi ZHANG<sup>1</sup>, Guang Yan YU<sup>1</sup>

**Abstract:** *In the present case report, a rare congenital fistula of the accessory parotid gland is discussed, including aetiology, methods and imaging for diagnosis and treatment options.*

**Key words:** *accessory parotid gland, fistula, salivary gland fistula*

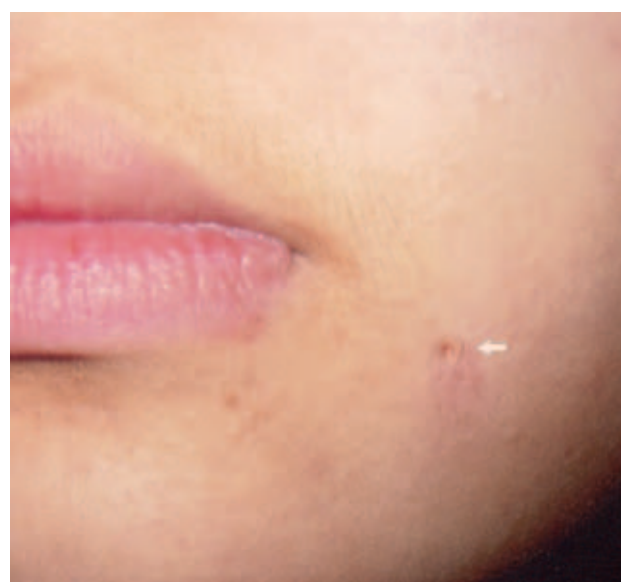Accessory parotid gland tissue is defined as a salivary tissue adjacent to Stensen's duct and apart from the main body of the parotid gland. As judged by anatomical dissections, 21% of human parotid glands manifest as accessory tissue<sup>1</sup>. The common diseases in parotid gland may also occur in the accessory parotid gland. Salivary fistulae may be categorised into two groups: congenital and acquired. Many of these fistulae belong to the latter group and arise secondarily to trauma, inflammation and superficial parotidectomy<sup>2</sup>. Congenital fistulae are extremely rare. This report presents a case of a congenital fistula of the accessory parotid gland.

### Case Report

A 13-year-old girl was referred to the Department of Oral and Maxillofacial Surgery, Peking University School of Stomatology, because of watery discharge from a fistula on the facial skin since birth. Her medical and family histories were normal without any prior medication. There was no complaint of pain or xerostomia. Physical examination revealed a fistula opening at the facial skin surface approximately 2 cm posterior to the angle of the left commissure of the lips. When squeezing

the left buccal region, the fistula discharged some clear and serous fluid (Fig 1a). There was a palpable mass on the buccal region 3 × 2 × 1 cm in size. An aural appendage was found near the left auricle. Intraoral examination had shown bilateral orifices at normal positions for Stensen's and Wharton's ducts with normal salivary outflow.

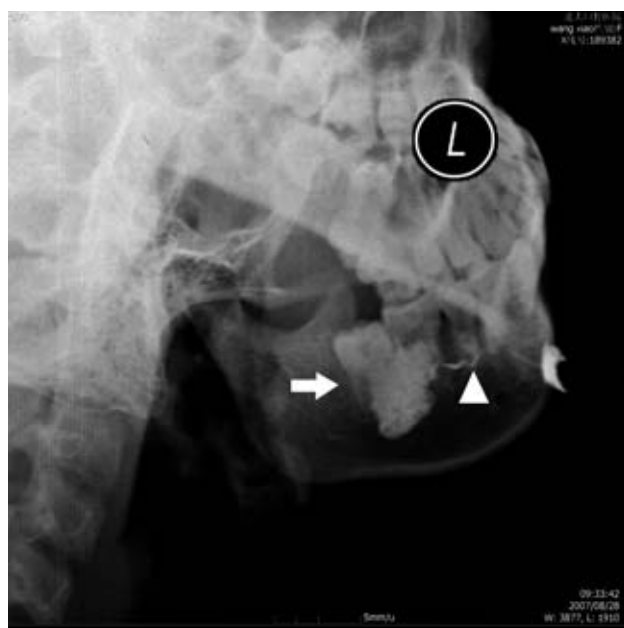A sialogram obtained following injection of contrast medium (40% iodinated oil) into the fistula revealed a gland-like density image (Fig 1b) on the buccal region,



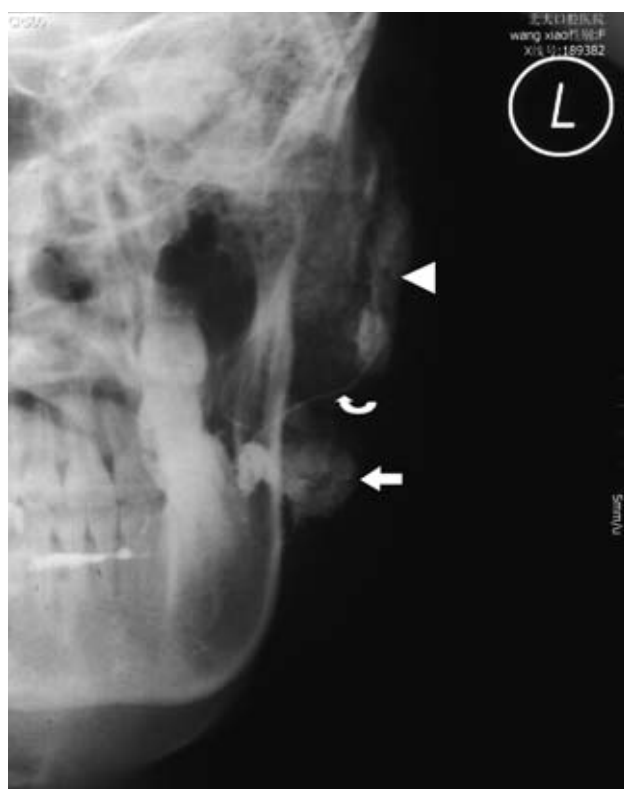
**Fig 1a** The fistula orifice (arrow) at the facial skin surface approximately 2 cm posterior to the angle of the left commissure of the lips. The serous fluid discharged from the fistula when buccal region was squeezed.

<sup>1</sup> Department of Oral and Maxillofacial Surgery, Peking University School and Hospital of Stomatology, Beijing, P.R. China.

**Corresponding author:** Dr Guang Yan YU, Department of Oral and Maxillofacial Surgery, Peking University School and Hospital of Stomatology, #22 Zhongguancun Nandajie, Beijing 100081, P.R. China. Tel: 86-10-62179977 ext 2578; Fax: 86-10-62173402. E-mail: gyyu@263.net



**Fig 1b** Lateral view of sialogram following injection of contrast medium into fistula showed a gland-like density image (arrow) on the buccal region, with its duct running anterior-inferiorly to the fistula orifice (arrowhead).



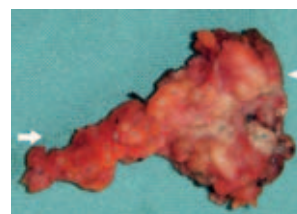
**Fig 1c** Anterior view of sialogram following injection of contrast medium through Stensen's duct (curved arrow) showed that the left parotid gland was on lateral of the left mandibular ramus and the prior gland-like density image (arrow) was anterior and inferior to the parotid gland.

with its duct running anterior-inferiorly to the fistula orifice. When the contrast medium was injected through the left Stensen's duct 5 hours later, the left parotid gland was visible on the lateral side of the mandibular ramus and the prior gland-like density image was anterior and inferior to the parotid gland (Fig 1c). Thus, the diagnosis of an accessory parotid gland fistula was established.

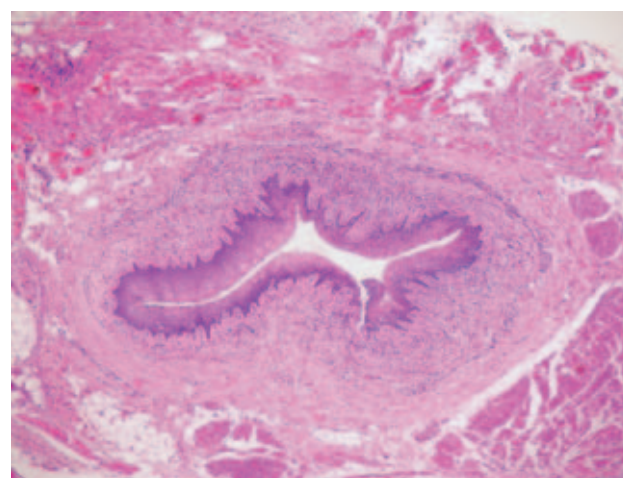
Under general anaesthesia, the accessory parotid gland was removed by buccal mucosa incision. Intra-operatively, methylthioninium chloride was injected into the left Stensen's duct and fistula to stain the normal parotid gland and the accessory parotid gland. The accessory parotid gland was found under the Stensen's duct. A ring-shaped incision with a diameter of approximately 5 mm was made around the fistula orifice and dissected toward the accessory gland. The accessory gland and the fistula were removed together (Fig 2a).

Histological examination showed that the fistula was lined with keratinising stratified squamous epithelium (Fig 2b) and the accessory gland comprised serous acini with inflammatory cell infiltration (Fig 2c).

The post-operative course was uneventful without infection of the incision and injury of the Stensen's duct. No discharge of saliva to the facial skin was found after surgery.



**Fig 2a** Operative specimen of the accessory parotid gland (arrowhead) and its fistula (arrow).



**Fig 2b** Histological examination showed that the fistula was lined with keratinising stratified squamous epithelium. Haematoxylin-eosin stain. Original magnification  $\times 40$ .

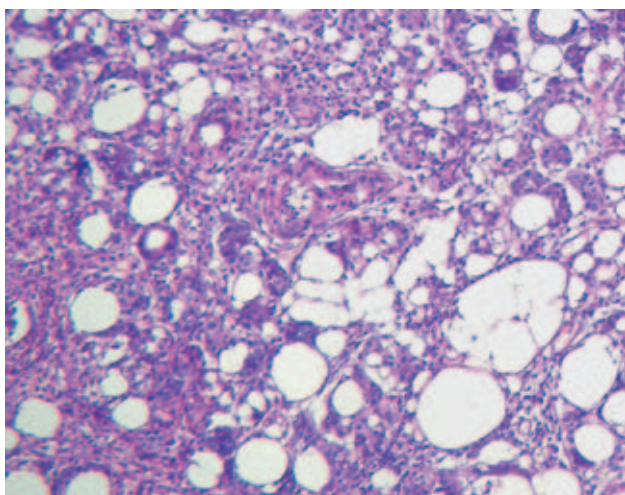


Fig 2c Histological examination showed that accessory gland comprised serous acini, with inflammatory cell infiltration. Haematoxylin-eosin stain. Original magnification  $\times 100$ .

## Discussion

Salivary fistulae can be divided into two groups: congenital and acquired. The acquired salivary fistulae are frequently caused by injuries, inflammation and parotid gland operations<sup>2</sup>. However, the congenital salivary fistulae are very rare and have been reported sporadically in the literature. Congenital salivary fistulae originate from the parotid gland<sup>3,4</sup>, submandibular gland, and ectopic salivary gland<sup>5,6</sup>. The sites of opening of the fistulae are always in the retroauricular region, the facial skin of the cheek<sup>3,7</sup>, cervical region<sup>8</sup>, submental area<sup>9</sup>, and external auditory canal<sup>10-12</sup>. Congenital fistulae from accessory parotid gland have typical sites of fistulous opening at the facial skin of the cheek near the mouth angle and are almost always accompanied by an aural appendage<sup>13</sup>.

The term 'accessory parotid gland' refers to lobules of parotid salivary tissue that drain into Stensen's duct but are separated from the main body of the gland. Accessory parotid glands occur rather frequently. In a study by Frommer<sup>1</sup>, 21% of dissections revealed clearly detached accessory glands at variable distances from the main gland. The accessory gland usually has one major tributary emptying into Stensen's duct, and two or more are occasionally observed. In the present case, the abnormal parotid tissue was below Stensen's duct. Although the communication of the abnormal tissue with Stensen's duct was not demonstrated in radiographic fistulography, it was found intraoperatively after injection of methylthioninium chloride into the fistula. Therefore, accessory parotid gland fistula is a more appropriate term than aberrant or ectopic parotid gland fistula in this case.

Embryologically, the development of the major salivary glands begins in the second month of foetal development<sup>14</sup>. During intrauterine development, the parotid gland develops as an outgrowth from the oral cavity as buds, spreading posteriorly towards the ear. The location of anlage develops into the opening of the duct. In cases where an excess parotid gland anlage develops from the epithelium of the primary oral fossa, an accessory parotid gland with a duct lying parallel to Stensen's duct may occur<sup>3</sup>.

The aetiology of the congenital salivary fistula is not explicit. Yamasaki et al<sup>3</sup> proposed that the excess parotid gland anlage may have proliferated from the original epithelium of the oral fossa and grown posteriorly and superiorly apart from the original parotid gland to form an accessory parotid gland. Gilbert et al<sup>4</sup> considered that it was possible that the primitive parotid bud developed from the edge of the maxillary process, in such a way that subsequent fusion of the processes leaves the parotid opening external rather than internal. In the present case, the fistula was accompanied by an aural appendage, which indicates that it may be related to the abnormalities of the first and second branchial arches.

Imaging is fundamental for diagnosis of salivary fistula. Radiographic sialography and fistulography are useful techniques. Through infusion of oil- or water-based iodine contrast medium, the architecture of the salivary duct system is visualised radiographically<sup>15</sup>. More recently, emphasis has been placed on computerised tomography (CT), magnetic resonance imaging (MRI) and salivary gland scintigraphy. CT sialography and CT fistulography may be helpful in distinguishing intrinsic from extrinsic lesions, differentiating benign from malignant tumours, but they fail to delineate the image of the parotid duct. MR sialography is non-invasive, and a promising alternative to radiographic sialography. MRI has been widely used for demonstrating parenchymal lesions in the salivary glands, and recent advances in MR techniques enable the direct visualisation of the salivary gland duct and its major branches without use of contrast medium<sup>16</sup>.

Although external salivary fistulae may be treated with drugs or irradiation, surgical therapy is the first choice for management. However, some authors recommend translocation of the fistula orifice to the oral cavity<sup>3,4</sup>. In the present case, resection of the accessory parotid gland and its fistula was performed, because this patient had bilateral normal parotid glands and normal secretion function. If the operation of translocation of fistula into oral cavity was performed, the possibility of the remaining scar in the orifice of the duct might cause duct obstruction.

## Acknowledgements

We are grateful to Dr Hai Yan LUO, Department of Oral Pathology, Peking University School of Stomatology, Beijing, P.R. China, for her kind assistance in performing the histological examination. We also thank Dr Deng Gao LIU, Department of Oral Radiology, Peking University School of Stomatology, Beijing, P.R. China, who assisted in performing the radiographic studies.

## References

1. Frommer J. The human accessory parotid gland: its incidence, nature, and significance. *Oral Surg Oral Med Oral Pathol* 1977;43:671-676.
2. Ananthakrishnan N, Parkash S. Parotid fistulas: a review. *Br J Surg* 1982;69:641-643.
3. Yamasaki H, Tashiro H, Watanabe T. Congenital parotid gland fistula. *Int J Oral Maxillofac Surg* 1986;15:492-494.
4. Gilbert PM. Congenital external fistulae of the parotid duct. *Br J Plast Surg* 1987;40:99-101.
5. Soucy P. Congenital cervical salivary fistula. *Can J Surg* 1985;28:130-131.
6. McFerran DJ, Phillips RR. Case report: congenital fistula between the submandibular gland and the oropharynx. *Br J Radiol* 1993;66:561-562.
7. Zhao K, Wang LM, Qi DY. Congenital extraoral fistula from an auxiliary parotid gland. *J Oral Maxillofac Surg* 1992;50:752-753.
8. Rothner AD. Aberrant salivary fistulas. *J Pediatr Surg* 1973;8:931-933.
9. Uekusa Y, Matsumoto K, Ohmae M, Sakuda M. Congenital submental salivary fistula. *Int J Oral Maxillofac Surg* 1999;28:400.
10. Sharma PD, Dawkins RS. Patent foramen of Huschke and spontaneous salivary fistula. *J Laryngol Otol* 1984;98:83-85.
11. Tasar M, Yetiser S. Congenital salivary fistula in the external auditory canal associated with chronic sialoadenitis and parotid cyst. *J Oral Maxillofac Surg* 2003;61:1101-1104.
12. Janke PG, Rivron RP. An unusual case of otorrhoea due to parotid salivary fistula. *Br J Radiol* 1988;61:509-511.
13. Moon WK, Han MH, Kim IO, Sung MW, Chang KH, Choo SW, Han MC. Congenital fistula from ectopic accessory parotid gland: diagnosis with CT sialography and CT fistulography. *Am J Neuroradiol* 1995;16:997-999.
14. Avery JK. Oral development and histology. New York: Thieme, 1994:352-356.
15. Kalk WWI, Vissink A, Spijkervet FKL, Roodenburg JLN. Morbidity from parotid sialography. *Oral Surg Oral Med Oral Pathol Oral Radiol Endod* 2001;92:572-575.
16. Jungehulsing M, Fischbach R, Schroder U, Kugel H, Damm M, Eckel HE. Magnetic resonance sialography. *Otolaryngol Head Neck Surg* 1999;121:488-494.