
Long-term Stability of Combined Orthodontic-surgical Treatment of Skeletal Open Bite: A Retrospective Study

Yun DING¹, Nils-Claudius Gellrich², Rainer Schwestka-Polly³,
Dirk Wiechmann³

Objective: *To study long-term skeletal and dento-alveolar stability 15 years after surgical-orthodontic correction of skeletal open bite.*

Methods: *Ten open bite patients (8 females and 2 males) who had undergone orthodontic treatment in combination with bimaxillary surgery at Hannover Medical School were reviewed. All patients underwent Le Fort I osteotomies combined with bilateral sagittal split osteotomy. The cephalometric records of these patients were examined at the start of orthodontic treatment (T1), before surgery (T2), immediately after surgery (T3), medium-term after surgery (average 1.5 years, T4) and long-term after surgery (average 15 years, T5). Eight skeletal and five dental cephalometric measurements were selected. Skeletal and dento-alveolar changes were evaluated.*

Results: *Moderate skeletal relapse has been observed 15 years after surgery in skeletal open bite patients treated by bimaxillary surgery. Approximately half of the total surgical changes in PP-SN, MP-SN and ANS-Me remained. Two-thirds of surgical changes in N-Me, N-ANS and S-Go remained. Except that the anterior part of maxilla relapsed completely 1.5 years after surgery, other skeletal relapses occurred mainly in the late follow-up period. Overbite remained quite stable 15 years after surgery, which was mainly due to the upper and lower incisors eruption during the long-term period.*

Conclusion: *Treatment of skeletal open bite via Le Fort I and bilateral sagittal split osteotomies appears to be a clinically successful and stable procedure.*

Correction of open bite has been considered to be a challenge for orthodontists. The aetiology of open bite has been considered to be multi-factorial. Some researchers have reported that open bite is induced by local or habitual factors, such as abnormal tongue, lip or cheek activity during mastication, swallowing and

speech¹, thumb sucking or mouth breathing. This type of open bite can be successfully treated by removing the functional aetiologies with orthodontic or orthopaedic appliances, or by tonic training of the perioral musculature along with tongue posture retraining. Open bite is also thought to be induced by skeletal deformities and should be treated by a combined orthodontic and orthognathic approach.

The surgical modalities for skeletal open bite have shifted over the years from mandibular osteotomies to maxillary procedures². Open bite correction through anticlockwise rotation of the mandible and intermaxillary wire fixation was abandoned because of the instability associated with this technique. Currently, superior repositioning and tilting of the maxilla, with or without bilateral sagittal split osteotomy (BSSO) has become the commonly used technique³⁻⁵.

¹ The Second Dental Center, Peking University, School and Hospital of Stomatology, Beijing, P.R. China.

² Department of Oral and Maxillofacial Surgery, Hannover Medical School, Hannover, Germany.

³ Department of Orthodontics, Hannover Medical School, Hannover, Germany.

Corresponding author: Dr. Yun DING, The Second Dental Center, Peking University School and Hospital of Stomatology, A2 Anli Garden, No.66 Anli Road, Yayuncun, Chaoyang District, 100101, Beijing, P.R. China. Tel: 86-10-64906556. E-mail: yunding666@126.com

In recent years, many studies have reported on the stability of maxillary surgery, but the results are still conflicting. Proffit et al⁶ reported a study on 61 patients who had their maxilla impacted by the Le Fort I down fracture technique, and found a 95% vertical stability at the one year post-operative stage. Lo and Shapiro⁷ examined the stability of maxillary surgery for open bite correction. They found that overbite decreased 0.82 mm on average during the 5-year 10-month follow-up, and 25% percent (10 of the 40) of the patients had no incisal overlap and were therefore considered to be unstable.

Controversy also exists as to the stability of the bimaxillary approach⁸⁻¹¹. Swinnen et al¹² reported a study on one-year follow up stability of 37 skeletal open bite patients treated by bimaxillary surgery. Although the clockwise rotation of the palatal plane (1.7 degrees) relapsed completely within the first post-operational year, overbite remained stable one year after surgery. Hoppenreijts et al¹³ reported that the skeletal open bite patients, treated with Le Fort I osteotomy with or without BSSO, exhibited good skeletal stability of the maxilla. The mean overbite at a 69 months follow-up was 1.24 mm. Some studies have shown that bimaxillary osteotomies could result in less mandibular but more maxillary relapse than each of the separate osteotomies^{8,9}, while others have reported a comparable relapse tendency^{10,11}.

Although there are a number of reports on the stability of surgical correction of skeletal open bite, there are no reports on long-term changes of more than 10 years. It will be of great interest to know the long-term skeletal and dental changes with skeletal open bite treated by bimaxillary surgery. Such knowledge would provide some insights into the causes of the long-term post-surgical changes and also provide more information for developing new modifications of the surgical procedure.

This paper reports the stability of more than 15 years post-surgery for patients in the Hannover Medical School who had bimaxillary surgical correction of skeletal open bite via Le Fort I osteotomy with simultaneous ramus osteotomies.

Materials and Methods

Sample

The records of 10 patients (8 females and 2 males) with skeletal open bite (no vertical overlap) treated by combined Le Fort I osteotomy and bilateral sagittal splitting of the mandibular ramus were reviewed. All patients were selected from the files at the orthodontic department and received orthodontic-surgical treatment at Hannover Medical School between 1982 and 1990.

The inclusion criteria were as follows. 1) The documentation was complete, including all the cephalograms taken at 5 occasions, i.e. at the start of the orthodontic treatment (T1), before surgery (T2), immediately after surgery (T3), medium-term after surgery, average 1.5 years (T4) and long-term after surgery, average 15 years (T5). 2) All the lateral head films had to be of sufficient quality to ensure adequate tracing. 3) Patients were of Caucasian origin. 4) Patients did not have severe craniofacial disorders such as cleft palate or hemifacial microsomia. 5) Patients had tongue-thrusting habits.

The average age of the patients was 24 years 5 months, ranging from 19 years to 41 years 4 months of age. All the patients had an increased lower face height and an increased mandibular plane angle, with a mean value mandibular plane angle of approximately 41.5 degrees. The average open bite of the patients was -3.2 mm with a range between -1.5 mm and -8.0 mm.

The post-operative follow-up period was divided into medium-term and long-term follow-up. The medium-term follow-up period ranged from 0.8 years to 2.5 years, with a mean of 1.5 years. The long-term follow-up period ranged from 13 years to 18 years, with a mean of 15 years.

Orthodontic treatment

All patients received orthodontic treatment during the pre- and post-operative period. Pre-operative orthodontic treatment included alignment of the teeth over their respective basal bones, decompensation where required, levelling of the dental arches and adjustment of the width of the dental arches.

Surgical procedure

All operations were performed at the Department of Maxillofacial Surgery, Hannover Medical School, between 1982 and 1990. Surgery was performed after the rate of growth was determined to have declined to adult levels. All cases were treated with superior surgical repositioning and tilting of the maxilla and bilateral sagittal split osteotomy (BSSO). The conventional down-fracture technique of the osteotomised maxilla was followed by rigid fixation using mini-plate osteosynthesis with 4 plates and suspension wire to the infraorbital rim. The average fixation period ranged from 4 months to 14 months, with a mean of 6.7 months. Fixation of the mandibular fragments was achieved by means of ramal anterior border intra-osseous wire ligatures and circummandibular wire ligatures. The remaining fixation period ranged from 4 months to 14 months, with a mean

TABLE 1 Cephalometric measurements definitions

Measurements	Definition
Skeletal measurements	
MP-SN (°)	The angle made by mandible plane (MP) and the frontal cranial basal plane (SN)
MP-PP (°)	The angle made by mandible plane (MP) and the palatal plane (PP)
PP-SN (°)	The angle made by palatal plane (PP) and the frontal cranial basal plane (SN)
N-Me (mm)	Anterior facial height: the distance between N and Me
N-ANS (mm)	Upper facial height: the distance between N and ANS
ANS-Me (mm)	Lower facial height: the distance between ANS and Me
S-Go (mm)	Posterior facial height: the distance between S and Go
S-Go/N-Me (%)	The ratio of posterior facial height to anterior facial height
Dental measurements	
Overbite (mm)	The distance between the perpendiculars from the incisal edges of the maxillary and mandibular incisors to the N-Me line
U1-PP (mm)	The vertical distance from the upper incisal edge to the palatal plane (PP)
U6-PP (mm)	The vertical distance from the upper first molar mesial cusp to the palatal plane (PP)
L1-MP (mm)	The vertical distance from the lower incisal edge to the mandibular plane (MP)
L6-MP (mm)	The vertical distance from the lower first molar mesial cusp to the mandibular plane (MP)

of 6 months. Intermaxillary fixation with fixed orthodontic appliances and constructed splints were used for 4 to 7 weeks, with an average of 5.2 weeks.

Cephalometric analysis

All the cephalograms were obtained with the teeth in centric occlusion and the lips in a relaxed position. Magnification for linear measurements was 8%, which was corrected. Radiographs were traced on acetate paper by the same investigator (Y.D.). Cephalometric landmarks identified and the reference lines used are shown in Fig 1. Definitions of cephalometric measurements are presented in Table 1. Twenty-six cephalometric landmarks were selected. Eight skeletal and five dental dimensions were measured.

Statistic analysis

All statistics were performed with SPSS software (SPSS, Inc., Chicago, USA). The analysis of frequency distribution showed the samples were normally distributed in general. Statistical analysis of the data was made using the Student *t* test. For all statistical analyses, the confidence level $p < 0.05$ was considered significant.

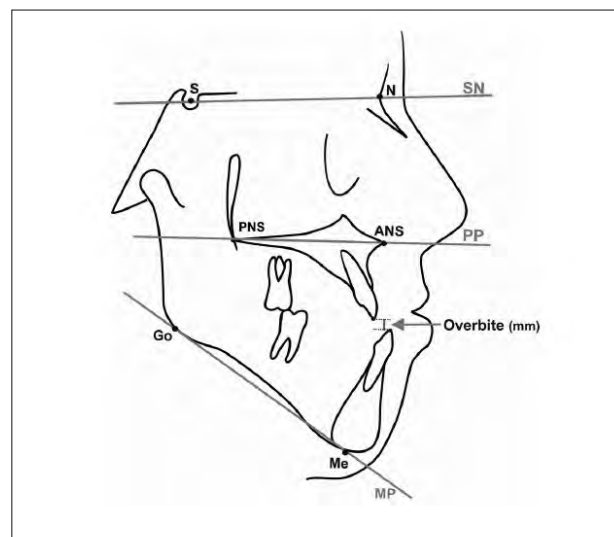


Fig 1 Cephalometric analysis.

Measurement reliability

The combined error of tracing and measurement was determined by tracing 10 randomly selected cephalometric radiographs at least 4 weeks after the first tracing and by repeating the measurements. Differences between the original and the retraced cephalometric radiographs were statistically analysed using paired *t* tests. The com-

TABLE 2 Mean values of variables at the start of orthodontic treatment (T1), pre-operatively (T2), immediately post-operatively (T3), 1.5 years post-operatively (T4), and 15 years post-operatively (T5)

Time intervals	T1		T2		T3		T4		T5		P
	Mean	SD	Mean	SD	Mean	SD	Mean	SD	Mean	SD	
Skeletal changes											
MP-SN (°)	41.5	5.3	42.0	4.9	40.7	6.9	40.7	6.7	41.6	6.1	NS
PP-SN (°)	10.5	2.9	10.7	3.0	15.5	8.0	15.4	6.8	13.0	5.7	***
MP-PP (°)	31.1	5.2	31.3	5.2	25.2	7.8	25.3	7.2	28.6	7.1	***
N-Me (mm)	123.8	7.3	124.1	7.0	119.5	6.9	119.7	6.8	121.4	6.1	***
N-ANS (mm)	52.2	3.0	52.4	2.9	50.3	3.4	51.1	3.3	50.9	2.4	**
ANS-Me (mm)	71.6	5.8	71.8	5.5	69.2	5.9	68.5	6.1	70.7	5.3	***
S-Go (mm)	73.9	6.2	73.9	6.2	71.0	6.1	71.4	6.6	72.1	6.3	*
S-Go/N-Me (%)	60.7	4.1	60.5	4.2	60.7	5.5	60.9	4.7	60.7	4.4	NS
Dental changes											
Overbite (mm)	-3.2	2.1	-3.2	2.2	0.6	1.8	1.6	0.7	1.5	0.9	***
U1-PP (mm)	26.7	3.5	27.0	3.4	27.5	3.7	27.6	3.9	29.6	3.4	**
U6-PP (mm)	24.7	2.1	24.7	2.0	24.5	2.2	24.0	1.9	24.5	1.3	NS
L1-MP (mm)	40.4	3.9	40.6	4.0	40.7	3.6	41.1	3.8	42.6	4.3	**
L6-MP (mm)	31.7	3.6	32.2	3.4	32.1	3.3	31.7	3.9	31.9	3.4	NS

*P<0.05; **P<0.01; ***P<0.0001; NS, not significant

TABLE 3 Mean changes of skeletal and dento-alveolar measurements pre-operatively (T1-T2), intra-operatively (T2-T3), early post-operatively (T3-T4), late post-operatively (T4-T5), total post-operatively (T3-T5) and the total treatment changes (T1-T5)

Skeletal changes	T1-T2		T2-T3		T3-T4		T4-T5		T3-T5		T1-T5	
	Mean	SD	Mean	SD	Mean	SD	Mean	SD	Mean	SD	Mean	SD
MP-SN (°)	-0.5	2.8	1.3	2.8	0.0	2.8	-0.9	2.8	-0.9	2.8	-0.1	2.8
PP-SN (°)	-0.2	4.1	-4.8**	4.1	0.1	4.1	2.4*	4.1	2.5*	4.1	-2.5*	4.1
MP-PP (°)	-0.2	3.8	6.1***	3.8	-0.1	3.8	-3.3**	3.8	-3.4**	3.8	2.5*	3.8
N-Me (mm)	-0.3	2.5	4.6***	2.5	-0.2	2.5	-1.7*	2.5	-1.9*	2.5	2.4**	2.5
N-ANS (mm)	-0.2	1.9	2.1**	1.9	-0.8*	1.9	0.2	1.9	-0.6	1.9	1.3*	1.9
ANS-Me (mm)	-0.2	0.7	2.6**	0.7	0.7	0.7	-2.2**	0.7	-1.5*	0.7	0.9	0.7
S-Go (mm)	0.0	3.5	2.9**	3.5	-0.4	3.5	-0.7	3.5	-1.1	3.5	1.8	3.5
S-Go/N-Me (%)	0.2	3.2	-0.2	3.2	-0.2	3.2	0.2	3.2	0.0	3.2	0.0	3.2
Dental Changes												
Overbite (mm)	0.0	2.2	-3.8***	2.2	-1.0	2.2	0.1	2.2	-0.9	2.2	-4.7***	2.2
U1-PP (mm)	-0.3	2.5	-0.5	2.5	-0.1	2.5	-2.0**	2.5	-2.1*	2.5	-2.9**	2.5
U6-PP (mm)	0.0	1.3	0.2	1.3	0.5	1.3	-0.5	1.3	-0.0	1.3	0.2	1.3
L1-MP (mm)	-0.2	0.9	-0.1	0.9	-0.4	0.9	-1.5**	0.9	-1.9**	0.9	-2.2**	0.9
L6-MP (mm)	-0.5	1.3	0.1	1.3	0.5	1.3	-0.2	1.3	0.3	1.3	-0.2	1.3

*P<0.05; **P<0.01; ***P<0.0001

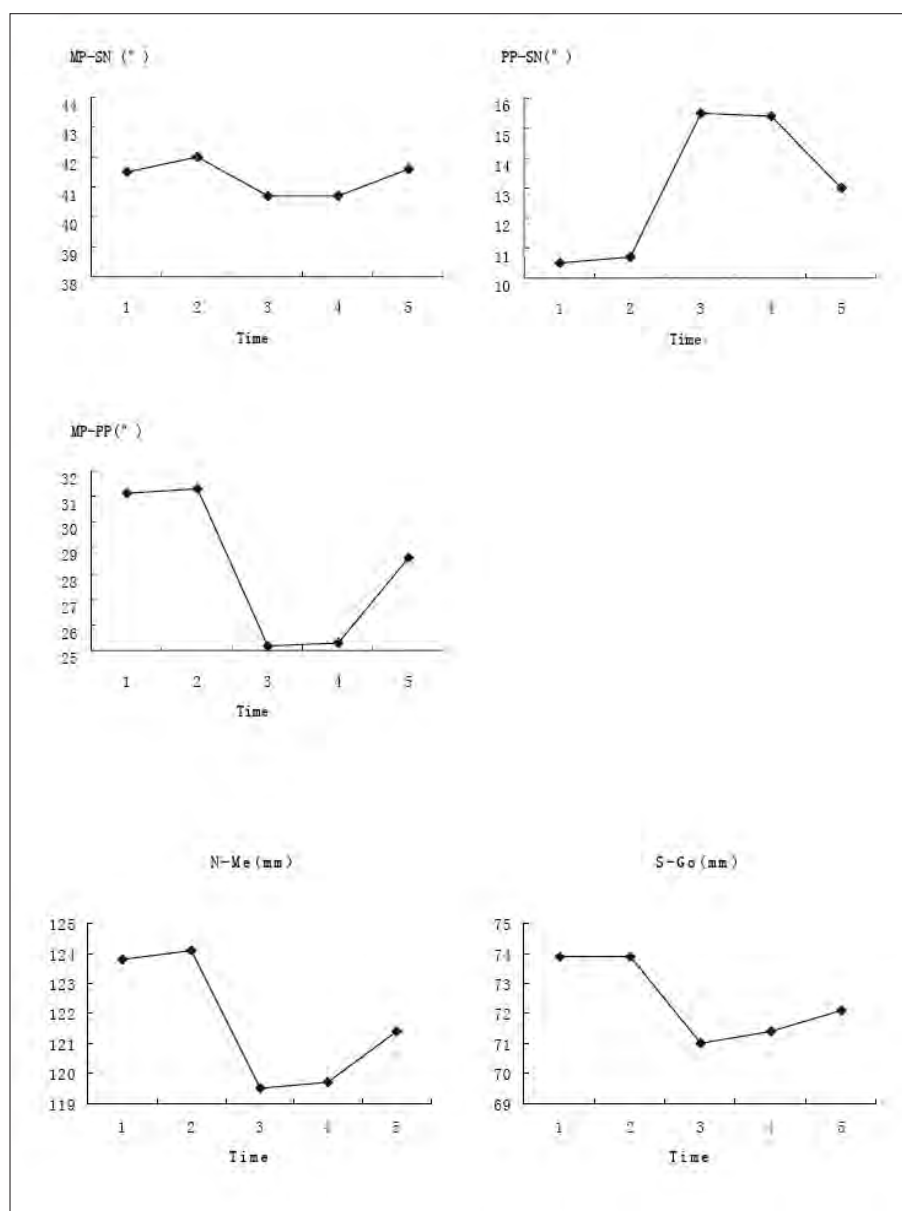


Fig 2 Post-surgical skeletal changes (mean values). 1) T1 (the start of orthodontic treatment), 2) T2 (before surgery), 3) T3 (immediately after surgery), 4) T4 (1.5 years after surgery) and 5) T5 (15 years after surgery).

bined tracing and measurement errors were not significant at the 0.05 level.

Results

The results of the cephalometric analysis are shown in Tables 2 and 3.

Skeletal changes

Mandibular plane angle (MP-SN)

Mandibular plane angle was reduced insignificantly by

1.30 degrees at surgery. Changes during the post-operative period were statistically insignificant (Fig 2).

Palatal plane angle (PP-SN)

There was a significant increase of 4.8 degrees in the palatal plane angle at surgery. It remained stable at the medium-term stage (1.5 years) with only 0.1 degree relapse. Most of the relapse (2.4 degrees) took place during the long-term follow-up. The net post-operative changes (T3–T5) were statistically significant. A late tendency (T4–T5) for anticlockwise rotation of the palatal plane was observed (Fig 2).

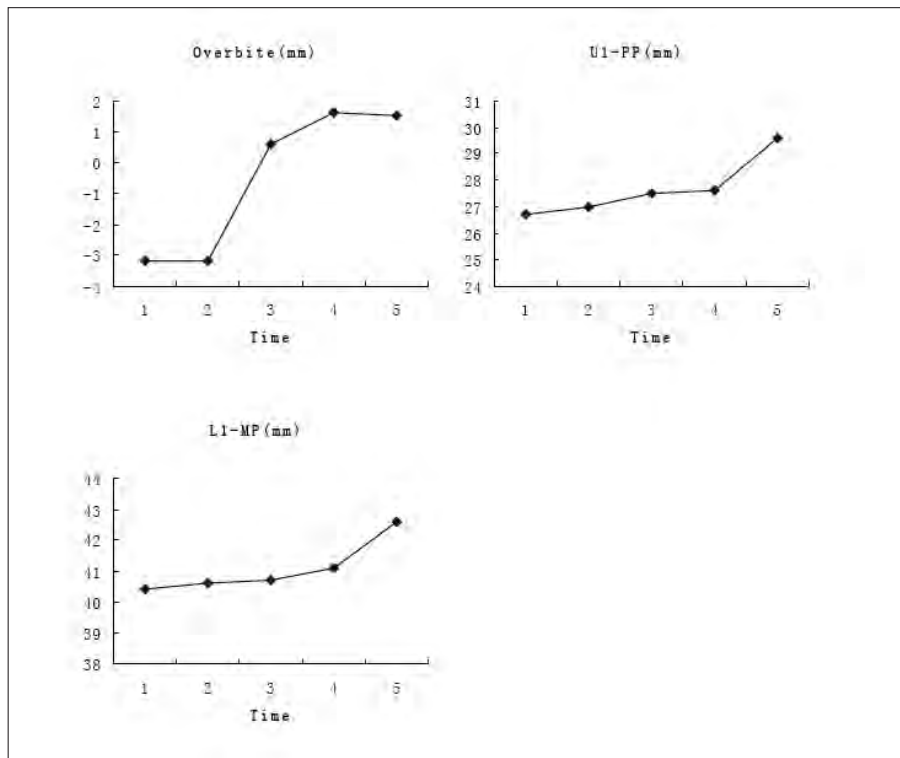


Fig 3 Post-surgical dental changes (mean values). 1) T1 (the start of orthodontic treatment), 2) T2 (before surgery), 3) T3 (immediately after surgery), 4) T4 (1.5 years after surgery) and 5) T5 (15 years after surgery).

Mandibular and maxillary plane angle (MP-PP)

There was a significant reduction of 6.1 degrees at surgery. During the medium-term follow-up, it remained quite stable. Most of the relapse (3.3 degrees) took place thereafter. The net post-operative changes (T3–T5) were statistically significant, and a late tendency (T4–T5) of relapse was observed (Fig 2).

Facial heights

Anterior facial height (N-Me) was reduced significantly by 4.6 mm at surgery, and remained quite stable during the medium-time follow-up. The major relapse (1.7 mm) was found in the long-term follow-up. The net post-operative changes (T3–T5) were statistically significant and a late tendency (T4–T5) of relapse was observed (Fig 2).

Posterior facial height (S-Go) was reduced significantly (2.9 mm) at surgery. During the whole follow-up period, it relapsed totally by 1.1 mm, which was not significant (Fig 2).

Anterior lower facial height (ANS-Me) was reduced significantly by 2.6 mm at surgery. It continued to reduce by 0.7 mm 1.5 years after surgery. During the long-term follow-up period, it relapsed by 2.2 mm. The net post-

operative changes (T3–T5) were statistically significant and a late tendency (T4–T5) of relapse was observed.

Anterior upper facial height (N-ANS) was reduced significantly by 2.1 mm at surgery. It showed a totally different relapse pattern when compared with other skeletal changes. An early tendency (T3–T4) of relapse was observed. The total relapse (0.8 mm) occurred completely within the medium-term follow-up period.

Dental changes

Overbite

Overbite was increased from -3.2 mm to +0.6 mm after surgery and continued to improve at medium-term stage to +1.6 mm. During the long-term follow-up, it remained quite stable, with an average mean of +1.5 mm 15 years after surgery. Only one out of the 10 patients (10%) had an anterior open bite (-0.5 mm) 15 years later (Fig 3).

Incisor position

No significant changes were found pre-surgically, during surgery and 1.5 years after surgery both in the maxillary and the mandibular incisors. Significant eruption in upper incisors (2.0 mm) and lower incisors (1.5 mm) was found during the long-term follow-up period (Fig 3).

Molar position

No significant changes were found pre-surgically, during surgery and after surgery both in the maxillary and mandibular molars.

In summary, the data showed that 15 years after surgery, approximately half of the total surgical changes in palatal plane rotation (PP-SN, MP-PP) and lower facial height (ANS-Me) remained. Two-thirds of those changes in anterior facial height (N-Me), upper facial height (N-ANS) and posterior facial height (S-Go) remained. The dental relationship and clinical acceptance remained relatively stable; nevertheless there was a moderate relapse in vertical skeletal measurements.

Discussion

Long-term stability of surgical correction of skeletal open bite is a major consideration in selecting the appropriate procedure. A number of studies reported the stability of skeletal open bite treated by surgery, but more than half of those studies only have one year for follow-up. Studies of more than one year of follow-up for orthognathic procedures showed that continuous changes in skeletal cephalometric landmarks were observed in that period. On the other hand, one year post-operation is likely to coincide with the removal of orthodontic appliances, and therefore the overbite would be positive. Therefore, although it may be possible to evaluate surgical stability one year post-operatively, overbite stability, which reflects both skeletal and dental movements, cannot truly be assessed unless a sufficient period of time has passed after the removal of the appliance. Lo and Shapiro⁷ reported that 25% of open bite patients with surgery did not have incisor overlap at the end of 69 months follow-up. Proffit et al¹⁴ reported that with 1–3 years, follow-up of open bite treated with bimaxillary surgery, face height increased more than 2 mm in 40% of the two-jaw surgery group, and 12% had an overbite decrease of 2–4 mm. It is important to continue to follow patients to improve the quality of the data for short and medium-term stability on which clinical decisions are presently based and to resolve questions about long-term stability.

The present study showed that none of the ten patients had an open bite relapse 1.5 years after surgery, and only one of them (10%) had an anterior open bite (-0.5 mm) recur 15 years after surgery. Since the data have comparable stability in the medium-term follow-up (1.5 years) to those reported by other studies^{11,13,15}, the data of long-term change (15 years) will shed light on the understanding of the skeletal and dental changes of skeletal open bite a long time after bimaxillary surgery.

The present data suggested that both the time course and amount of relapse of maxilla and mandible are different during the 15-year follow-up period. Apart from the anterior part of the maxilla (ANS), which showed complete relapse during the first 1.5-year follow-up period, all the other skeletal relapses, such as the downward movement of the posterior part of maxilla (PNS), the anticlockwise rotation of the palatal plane (PP-SN) and also the increase in the lower facial height (ANS-Me), were observed in the long-term follow-up period. Posterior facial height (S-Go) showed a continuous increase during the whole follow-up period. On the other hand, the amount of relapse in the upper and lower face was also different. This difference might be because the upper facial changes are mainly influenced by maxillary changes, but the lower facial changes are influenced by both the maxillary changes and also the mandibular changes.

A number of studies have reported the different stability between the maxilla and mandible in open-bite patients treated by bimaxillary surgery¹⁶⁻¹⁷. Moser and Freihofer¹⁸ reported that in skeletal open bite patients treated by bimaxillary surgery, the maxilla proved to be far more stable than the mandible. Lello¹⁹ reported similar results (within 5 years follow-up). The present 15-year follow-up study is also in agreement with this conclusion.

It could be postulated that moderate relapse in the skeletal position of the maxilla and mandible would predispose the recurrence of an anterior open bite. However, this was not seen, since no significant change in overbite could be clinically observed. Despite the amount of skeletal relapse in the long-term follow-up, the relative stability in dental relationship is surprising. The overbite of the present samples remained quite stable, and there was a significant increase in maxillary and mandibular incisor vertical position. Further investigation is required to elucidate why there was skeletal relapse long after surgical healing was complete, and why the amount of relapse toward open bite was insignificant.

It has been shown that tongue activity might play an important role in dental changes. Data from teeth eruption studies have suggested that heavy intermittent forces, like those from swallowing or other activities, have little or no effect on teeth eruption. Very light forces, such as that exerted by tongue or other soft tissues at rest, can stop eruption of teeth if they are maintained for 25 to 50% of the time²⁰. In the present study all the patients had tongue thrusting habits. Before surgery, the tongue always covered the maxillary or mandibular incisors, and perhaps this is the reason why there was no compensation in the incisors and anterior

open bite occurred. After surgery, the sagittal discrepancy of the two jaws was corrected and relatively good occlusion was obtained; the tongue had a relatively good position, so even post-surgical skeletal changes were obvious; maxillary and mandibular incisors erupted and compensated for the skeletal change; and even 15 years after surgery, overbite remained stable.

Conclusions

Cephalometric radiographs were evaluated to determine the long-term stability of bimaxillary treatment of skeletal open bite. Changes in the cephalometric measurements were evaluated a mean of 15 years after surgery. On the basis of statistical analysis, the following conclusions were made:

1. Moderate skeletal relapse was observed 15 years after surgery as determined by lateral cephalograms.
2. Approximately half of the total surgical changes in PP-SN, MP-PP and ANS-Me and two-thirds of those changes in N-Me, N-ANS and S-Go remained 15 years after surgery.
3. The anterior part of maxilla relapsed completely during the first 1.5 years. Other skeletal relapse occurred mainly in the late follow-up period.
4. Overbite remained quiet stable 15 years after surgery, which is mainly due to the maxillary and mandibular incisors erupting during the long-term period.
5. Treatment of skeletal open bite by means of a Le Fort I and bilateral sagittal split osteotomies appears to be a clinically successful and stable procedure.

Acknowledgements

We are very grateful to Dr. J.-L. Berten, Department of Orthodontics, Hannover Medical School, and Dr. P. Brachvogel, Department of Oral and Maxillofacial Surgery, Hannover Medical School, for respectively performing and supervising the clinical treatment of the patients in the present study.

References

1. Mason RM, Proffit WR. The tongue thrust controversy: background and recommendations. *J Speech Hear Disord* 1974;39:115-132.
2. Epker BN, Fish L. Surgical-orthodontic correction of open-bite deformity. *Am J Orthod* 1977;71:278-299.
3. Bell WH, McBride KL. Correction of the long face syndrome by Le Fort I osteotomy. A report on some new technical modifications and treatment results. *Oral Surg Oral Med Oral Pathol* 1977;44:493-520.
4. Epker BN. Superior surgical repositioning of the maxilla: long term results. *J Maxillofac Surg* 1981;9:237-246.
5. Hoppenreijts TJ, Freihofer HP, Stoelinga PJ et al. Condylar remodeling and resorption after Le Fort I and bimaxillary osteotomies in patients with anterior open bite. A clinical and radiological study. *Int J Oral Maxillofac Surg* 1998;27:81-91.
6. Proffit WR, Phillips C, Turvey TA. Stability following superior repositioning of the maxilla by LeFort I osteotomy. *Am J Orthod Dentofacial Orthop* 1987;92:151-161.
7. Lo FM, Shapiro PA. Effect of presurgical incisor extrusion on stability of anterior open bite malocclusion treated with orthognathic surgery. *Int J Adult Orthodon Orthognath Surg* 1998;13:23-34.
8. Brammer J, Finn R, Bell WH et al. Stability after bimaxillary surgery to correct vertical maxillary excess and mandibular deficiency. *J Oral Surg* 1980;38:664-670.
9. Hiranaka DK, Kelly JP. Stability of simultaneous orthognathic surgery on the maxilla and mandible: a computer-assisted cephalometric study. *Int J Adult Orthodon Orthognath Surg* 1987;2:193-213.
10. Hennes JA, Wallen TR, Bloomquist DS, Crouch DL. Stability of simultaneous mobilization of the maxilla and mandible utilizing internal rigid fixation. *Int J Adult Orthodon Orthognath Surg* 1988; 3:127-141.
11. Turvey TA, Phillips C, Zaytoun HS, Jr., Proffit WR. Simultaneous superior repositioning of the maxilla and mandibular advancement. A report on stability. *Am J Orthod Dentofacial Orthop* 1988;94:372-383.
12. Swinnen K, Politis C, Willems G et al. Skeletal and dento-alveolar stability after surgical-orthodontic treatment of anterior open bite: a retrospective study. *Eur J Orthod* 2001;23:547-557.
13. Hoppenreijts TJ, Freihofer HP, Stoelinga PJ, Tuinzing DB. Stability of orthodontic-maxillofacial surgical treatment of anterior open bite deformities. *Ned Tijdschr Tandheelkd* 2001;108:173-178.
14. Proffit WR, Bailey LJ, Phillips C, Turvey TA. Long-term stability of surgical open-bite correction by Le Fort I osteotomy. *Angle Orthod* 2000;70:112-117.
15. Denison TF, Kokich VG, Shapiro PA. Stability of maxillary surgery in openbite versus nonopenbite malocclusions. *Angle Orthod* 1989;59:5-10.
16. Schwestka-Polly R. Significance of the contour of the lateral surface of the maxilla for planning osteotomy lines in orthognathic surgery. *Int J Adult Orthodon Orthognath Surg* 1993;8:191-201.
17. Teuscher U, Sailer HF. Stability of Le Fort I osteotomy in class III cases with retropositioned maxillae. *J Maxillofac Surg* 1982;10:80-83.
18. Moser K, Freihofer HP. Erfahrungen mit der korrektur des skeletal offenen bisses durch sagittale spaltung des unterkiefers. *Fortschr d Kiefer- und Gesichtschir* 1981;26:64-73.
19. Lello GE. Skeletal open bite correction by combined Le Fort I osteotomy and bilateral sagittal split of the mandibular ramus. *J Craniomaxillofac Surg* 1987;15:132-136.
20. Gierie WV, Paterson RL, Proffit WR. Response of erupting human premolars to force application. *Arch Oral Biol* 1999;44:423-428.