

---

# Effect of Epimedium Grandiflorum Morr on Prevention and Treatment of Rat Mandible and Femur Bone Loss

Sheng Lin LI<sup>1</sup>, Kui Hua ZHANG<sup>1</sup>, Shi Feng YU<sup>2</sup>

**Objective:** To study the effect of Epimedium grandiflorum Morr (EG) on the prevention and treatment of bone loss of the mandible and femur in ovariectomised rats.

**Methods:** A total of 114 adult female Sprague-Dawley (SD) rats were ovariectomised. The effects of EG and oestradiol (ES) on prevention and treatment of bone loss were evaluated. For prevention, both drugs were given the day after ovariectomy. For treatment, the drugs were given 3 months after ovariectomy, when the animal model of osteoporosis was established. The bone density was determined with a densitometer. Newly synthesised collagen was fluorescently labelled with procion red.

**Results:** Three months after ovariectomy, the bone densities of the rat femurs and mandibles were markedly lower than those of the controls, indicating that osteoporosis was successfully established. Administration of EG and ES equally prevented osteoporosis of mandible and femur of ovariectomised rats, and to some extent increased bone density of osteoporosis rats.

**Conclusion:** EG was effective in the prevention of osteoporosis of the mandibles and femurs. EG was also somewhat effective in the treatment of osteoporosis of femurs.

**Key words:** Chinese herbal medicine, Epimedium grandiflorum Morr, mandible bone loss, osteoporosis

Osteoporosis is a common disease with features of gradual loss of mineral content and bone mass. Pathologic fracture may occur in the vertebrae, femur, radius, and even mandible. Bone loss during the early stages of oestrogen deficiency is clearly associated with

increased bone turnover. Oestrogen treatment has a bone-protective effect associated with decreasing bone turnover in ovariectomised (OV) rats. Bisphosphonate compounds and oestrogen both depress bone turnover with a similar mechanism. Mandible bone loss, similar to whole body bone loss, is closely related to the lack of oestrogen in menopausal women. Some studies have shown that in menopausal women, the rate of denture renewal in patients with osteoporosis is higher than for those without osteoporosis because of the absorption of the alveolar bone. Chinese herbal medicines have been used in traditional Chinese medicine (TCM) for a long time. They can have fewer side effects than the chemical reagents. The purpose of the present study is to evaluate the effects of a Chinese herbal medicine, *Epimedium grandiflorum* Morr (EG) on the prevention and treatment of bone loss of mandible in OV rats.

---

<sup>1</sup> Research Laboratory of Oral & Maxillofacial Surgery, Peking University School and Hospital of Stomatology Beijing, P.R. China.

<sup>2</sup> Department of Oral Pathology, Peking University, School and Hospital of Stomatology, Beijing, P.R. China.

**Corresponding author:** Dr. Sheng Lin LI, Research Laboratory of Oral & Maxillofacial Surgery, Peking University School and Hospital of Stomatology, #22 Zhongguancun Nandajie, Haidian District, Beijing 100081, P.R. China. Tel: 86-10-62179977 ext 2534; Fax: 86-10-62173402. E-mail: shenglin\_li@263.net

This study was supported by the Natural Science Foundation of China (39830430).

## Materials and Methods

Female adult SD rats (90 days old) weighing an average of 260 g were used in this study. The animal model of osteoporosis was produced by ovariectomy in 114 adult female SD rats. Ovariectomies were performed from a dorsal approach under 3% sodium pentobarbital anaesthesia. The excised ovaries were confirmed histologically. Preliminary experimentation showed that osteoporosis was evident, as there was loss of bone mass 3 months after ovariectomy. The experiment was divided into two parts. Part I was designed to examine the effect of EG on prevention of osteoporosis, and comprised four groups of rats: Normal group (14 intact rats), OV group (14 ovariectomised rats), OV+ES group (17 ovariectomised rats injected with oestradiol [Mingxing Pharmaceutical Corp, P.R. China] 0.5 mg/kg body weight everyday for 5 days a week for 3 months, with one week non-administration of oestradiol for every 3 weeks of administration), OV+EG group (17 ovariectomised rats were injected with EG extract equal to 0.6 g raw herb/kg body weight in the same procedure as OV+ES group). Part II was designed to examine the treatment effect on osteoporosis, and also contained four groups of rats: Normal group (14 intact rats), OV group (14 ovariectomised rats), OV+ES group (26 OV rats received oestradiol for 3 months after ovariectomy), OV+EG group (26 OV rats received EG for 3 months after ovariectomy).

All the rats were fed a normal diet of 25 g/day/rat. Exposure to light was the same for all subjects. Animals were weighed every week and sacrificed at the end of the experiment by injection with an overdose of sodium pentobarbital.

### *Measurement of bone density*

The radiograms of the femurs and mandibles were taken with soft X-ray (JIRA, Model ESM-2, Japan). To avoid image errors and to achieve the same grey scale, femurs or mandibles of the four groups were radiographed on one X-ray film (Fuji, Japan) at 35 kV, 5 mA, for 20 sec. The region of interest on the X-ray film was measured using a densitometer (Sakura, PDA-81, Japan) for radiographic density (transmitted density), with 3 mm-diameter measuring pore.

The mean and standard deviation of the radiographic density values in each group (Normal, OV, OV+ES and OV+EG groups) were determined. One-way analysis of variance (ANOVA) was used to test the differences between density values among the groups.

### *Fluorescent microscopy*

Fluorescence labelling was performed by injection with procion red at the dosage of 0.75 mg/kg body weight at 10 and 2 days before sacrifice. Procion red combined with bone collagen and was used to examine osteogenesis activity of bone. The soft tissues of mandible and femur were removed immediately after sacrifice and bones were fixed in 10% formalin. The fluorescence-labelled specimens were sectioned without decalcification at 50–100  $\mu\text{m}$  with Jung 1600 Saw Microtome (Leica, Germany) and observed with a fluorescent microscope under UV excitation.

## Results

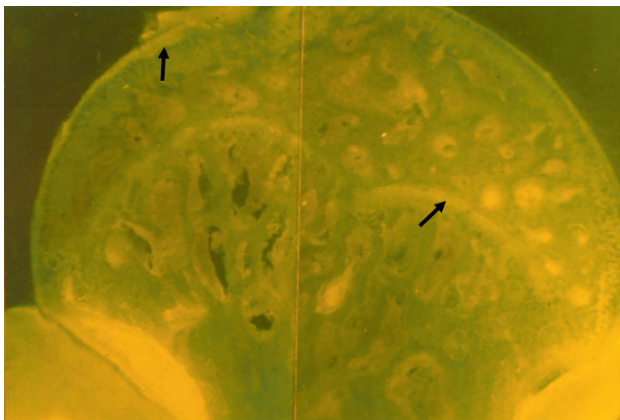
### *Bone density*

The bone density of the femurs and mandibles was examined as radiographic density of the films. The radiographic density was measured at the metaphysis of the femurs and the angle of the mandible. The higher the radiographic density measured by the densitometer, the lower the bone density, according to the principal of the densitometer.

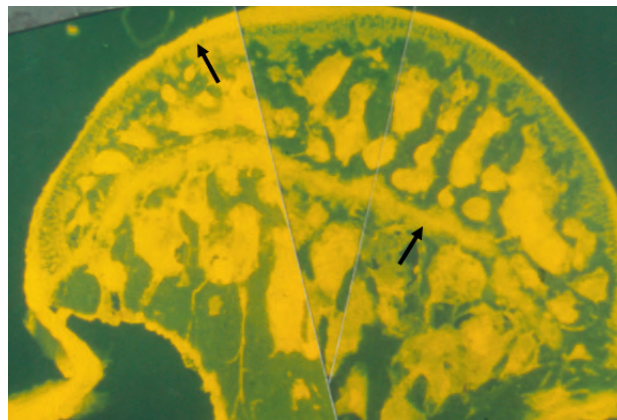
The radiographic densities of femurs in part I for the Normal, OV, OV+EG and OV+ES groups were  $0.817 \pm 0.075$ ,  $1.025 \pm 0.076$ ,  $0.678 \pm 0.070$  and  $0.603 \pm 0.055$ , respectively. It was demonstrated that 3 months after ovariectomy, the femur bone density of the OV group was markedly lower than that of the Normal group, showing that osteoporosis had occurred ( $p < 0.001$ ). The bone density of the OV group in femurs was also significantly lower than the OV+EG and OV+ES groups ( $p < 0.001$ ). Interestingly, the bone densities of femurs in EG group and ES group were higher than those of the Normal group, suggesting that EG not only prevented the occurrence of osteoporosis, but also increased the bone density ( $p < 0.001$ ).

The radiographic densities of mandibles in part I for Normal, OV, OV+EG and OV+ES groups were  $2.708 \pm 0.124$ ,  $3.158 \pm 0.315$ ,  $2.775 \pm 0.082$ , and  $2.725 \pm 0.175$ , respectively. The bone densities of the OV group in the mandible were significantly lower than those of the Normal group ( $p < 0.002$ ), demonstrating the bone loss of mandible when osteoporosis occurred. There was no difference among the Normal, OV+EG and OV+ES groups in bone density ( $p > 0.05$ ), which suggests that EG and ES were effective in prevention of mandibular bone loss in ovariectomised rats.

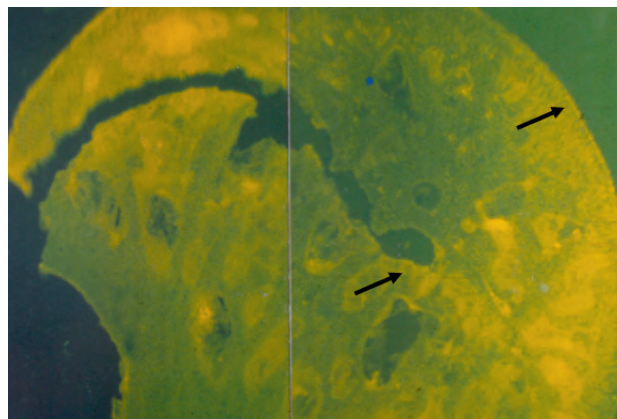
The radiographic densities of femurs in part II for Normal, OV, OV+EG and OV+ES groups were  $1.013 \pm 0.152$ ,  $1.253 \pm 0.137$ ,  $1.164 \pm 0.160$ , and  $1.148 \pm 0.126$ ,



**Fig 1** Femur head of Normal group in experimental part I, labelled with fluorescence, showed newly synthesised bone collagen with a bright yellow colour (arrows).



**Fig 2** Femur head of OV+EG group in experimental part I, labelled with fluorescence, showing stronger fluorescent intensity (arrows) than the Normal group both in quality and quantity, demonstrating active bone collagen synthesis during EG administration.



**Fig 3** Femur head of OV group in experimental part I, labelled with fluorescence, showing that the collagen synthesis was less active in bone marrow cavities and absent in the epiphysis and cartilage on the surface of femur head (arrows).

respectively. The bone densities of the femurs in the Normal group were markedly higher than those of the other groups ( $p < 0.001$ ). The bone densities of the OV+EG group were not significantly different from the OV+ES group ( $p > 0.05$ ). However, the bone densities of the OV+EG group and the OV+ES group were higher than those of the OV group ( $p < 0.05$ ), suggesting that to some extent EG had similar effect to oestradiol on the treatment of osteoporosis.

#### *Fluorescence labelling*

The femur head was sectioned in 100  $\mu\text{m}$ -thick sections. The procion red combined with newly synthesised bone

collagen was a bright yellow colour under UV excitation, demonstrating that some bone collagen synthesis occurred in the upper part of the femur head, bone marrow cavities and the epiphysis plate in the Normal group (Fig 1). The fluorescence intensity in the femur heads of the OV+EG group was much stronger than that of the Normal group, both in quality and quantity (Fig 2), demonstrating that there was more active bone collagen synthesis during EG administration. In the OV group, the fluorescence intensity was lower in bone marrow cavities and absent in the epiphysis and cartilage in the upper part of the femur head compared with the other groups, demonstrating that collagen synthesis was inactive in those areas (Fig 3).

## Discussion

The mechanism of *Epimedium* in prevention and treatment of osteoporosis is not clear. Liu et al<sup>1</sup> have shown that *Epimedium* extract can increase proliferation of the bone marrow. It may promote osteoblast proliferation and protein synthesis<sup>2</sup>. *Epimedium* contains some trace elements, such as Mn, Zn etc., and the amount of Mn in *Epimedium* is the highest among the studied Chinese herbs<sup>3</sup>. Experimental study has found that high concentrations of Mn can promote osteogenesis in cultured bone tissue<sup>4</sup>. Studies have revealed that Mn participates directly in Ca-P metabolism and that when serum concentration of Mn is raised, the serum calcium concentration decreases and calcium deposits in bone. Through endocrine and protein synthesis regulation, Mn and Zn may promote bone growth and fracture healing. Studies of the effect of *Epimedium* on the circulation system have shown that it can expand peripheral blood vessels to lower the resistance and improve microcirculation<sup>5</sup>. The above observations may partially explain the effects of *Epimedium* on prevention and treatment of osteoporosis in the present study. However, the accurate mechanism still needs further study.

The animal model of osteoporosis is usually used for the initial preclinical evaluation of new therapies designed to prevent postmenopausal bone loss<sup>6</sup>. The present study shows that osteoporosis could also cause mandible bone loss 3 months after ovariectomy.

In women, oestrogens are important for establishment of peak bone mass, for its maintenance, and for therapy of osteoporosis<sup>7</sup>. Oestrogen deficiency has been identified as the major risk for osteoporosis in women of all ages. It is generally agreed that therapy with oestrogen reduces bone turnover and increases bone mineral density. A recent meta-analysis of 37 prospective, randomised trials clearly demonstrated that oestrogen replacement therapy used for prevention of postmenopausal osteoporosis had a positive impact on bone mineral density or content. The main drug given was oestradiol, at a dose of 2 mg<sup>8</sup>. It was used in the present study for both prevention and treatment of rat osteoporosis. However, its possible negative impact on the induction of breast, uterine, or ovarian cancer remains controversial and limits its use<sup>9-11</sup>. Several studies showed that exposure to oestrogen alone substantially elevated the risk of endometrial cancer, and use of hormone replacement therapy might increase the risk of lobular, but not ductal, breast carcinoma in middle-aged women<sup>12,13</sup>. Currently available agents do not completely prevent or cure osteoporosis<sup>14-16</sup>. We therefore shift our attention to the Chinese herbs.

*Epimedium* is a family of several plants with the same pharmacological effect. The family consists mainly of

*Epimedium grandiflorum* Morr, *Epimedium brevicornum* Maxim, and *Epimedium sagittatum*<sup>17</sup>. Studies have shown that the extract has the same effects as the whole herb<sup>18</sup>. The present study has also shown that extract of *Epimedium* has a significant effect on the prevention of osteoporosis in ovariectomised rats, but less effect on the treatment of osteoporosis.

## References

1. Liu FC. [The effect of EG polysaccharide on the DNA synthesis of bone marrow cells in "yang-xu" model induced by hydroxyurea]. Chin J Chin Herb Med 1991;16:620-622 (in Chinese).
2. Yin XX, Chen ZQ, Liu ZJ, Ma QJ, Dang GT. Icarine stimulates proliferation and differentiation of human osteoblasts by increasing production of bone morphogenetic protein 2. Chin Med J (Engl) 2007;120:204-210.
3. Sai D. Experimental study of trace elements in *Epimedium*. Acta Chin Med Pharmacol 2001;29:50 (in Chinese).
4. Stern PH. Biphasic effects of manganese on hormone-stimulated bone resorption. Endocrinology 1985;117:2044-2049.
5. Wang YJ, Sun YL, Tang W, Xu H, Xu ZX. The effect of Icarin on cardiovascular system of experimental animal. Chin Herb Med 2007;38:97 (in Chinese).
6. Wronski TJ, Dann LM, Scott KS, Crooke LR. Endocrine and pharmacological suppressors of bone turnover protect against osteopenia in ovariectomized rats. Endocrinology 1989;125:810-816.
7. Bilezikian JP, Morishima A, Bell J, Grumbach MM. Increased bone mass as a result of estrogen therapy in a man with aromatase deficiency. N Engl J Med 1998;339:599-603.
8. Martina D. Primary and secondary prevention of postmenopausal osteoporosis with hormone replacement therapy. Osteoporosis update 1999. Xi'an: The Third International Congress on Osteoporosis 1999:176-185.
9. DiSaia PJ. Hormone replacement therapy in the gynecologic and breast cancer patient. Cancer Control 1996;3:101-106.
10. Chiechi LM, Secreto G. Factors of risk for breast cancer influencing post-menopausal long-term hormone replacement therapy. Tumori 2000;86:12-16.
11. Kenemans P, Stampfer M. Hormone replacement therapy and breast cancer. Eur J Obstet Gynecol Reprod Biol 1996;67:1-4.
12. Li CI, Weiss NS, Stanford JL, Daling JR. Hormone replacement therapy in relation to risk of lobular and ductal breast carcinoma in middle-aged women. Cancer 2000;88:2570-2577.
13. Persson I, Weiderpass E, Berakvist L et al. Risks of breast and endometrial cancer after estrogen and estrogen-progestin replacement. Cancer Causes Control 1999;10:253-260.
14. Bergkvist L, Persson I. Hormone replacement therapy and breast cancer. A review of current knowledge. Drug Saf 1996;15:360-370.
15. Crawshaw A. Carcinoma of the breast and hormone replacement therapy for osteoporosis. Int J Clin Pract 2000;54:99-103.
16. Lopes P. Menopausal hormone replacement therapy and risk of breast cancer. Implications for the treatment of osteoporosis in postmenopausal women. Rev Rhum Engl Ed 1996;63:309-311.
17. Xue F, Xu Z-M (eds). Chinese Herb Medicines. 2nd ed. Beijing: People's Medical Publishing House 1998:378-379 (in Chinese).
18. Liu FC. Recent studies on the clinical use and pharmacology of *Epimedium*. Chin Herb Med 1985;16:47-50 (in Chinese).