

Effect of Dental Implant System–Assisted Tooth Intentional Replantation in the Treatment of Anterior Teeth with Pathological Tooth Flaring, Drifting and Elongation in Patients with Stage III/IV Periodontitis: a Case Series

Ya Hui QIAO^{1,#}, Xin Yu ZHANG^{1,#}, Rui Qi BAI^{1,2}, Jing Wen CAI¹, Lin Lin ZHANG¹, Bin Jie LIU¹, Jun CHEN¹

Objective: To investigate the clinical effect of implant-assisted dental intentional replantation (IR) for the treatment of “drifted” anterior periodontally hopeless teeth (PHT).

Methods: The present authors recruited 22 patients with stage III/IV periodontitis who suffered drifting of the maxillary anterior teeth, with a total of 25 teeth. The PHT were extracted for in vitro root canal treatment (RCT). The root surface was smoothed and the shape was trimmed, and the alveolar socket was scratched. The dental implant system was used to prepare the alveolar socket according to the direction, depth and shape of the tooth implantation. The PHT were reimplanted into the prepared alveolar socket. The periodontal indicators were analysed statistically before and after surgery.

Result: Twenty-two patients who completed the full course of treatment, with a total of 25 PHT, had a successful retention rate of 88%. Mean periodontal probing depth (PPD) decreased by 2.880 ± 0.556 mm and 3.390 ± 0.634 mm at 6 months and 1 year, respectively, and clinical attachment loss (CAL) decreased by 2.600 ± 0.622 mm and 2.959 ± 0.731 mm at the same time points, respectively, showing significant improvement ($P < 0.05$).

Conclusion: Dental implant system–assisted IR can effectively preserve “drifted” natural PHT in patients with stage III/IV periodontitis.

Keywords: dental implant system–assisted, intentional replantation, periodontally hopeless teeth, stage III/IV periodontitis

Chin J Dent Res 2024;27(2):143–149; doi: 10.3290/j.cjdr.b5459589

1 Department of Periodontics and Oral Medicine, Xiangya Stomatological Hospital & Xiangya School of Stomatology, Central South University & Hunan Key Laboratory of Oral Health Research & Hunan Clinical Research Center of Oral Major Diseases and Oral Health & Academician Workstation for Oral-maxillofacial and Regenerative Medicine, Changsha, P.R. China.

2 Hospital of Stomatology, Zhongshan City, Zhongshan, P.R. China.

These two authors contributed equally to this work.

Corresponding authors: Dr Bin Jie LIU and Dr Jun CHEN, Department of Periodontics and Oral Medicine, Xiangya Stomatological Hospital, Changsha 410000, P.R. China. Tel: 86 13974843531; 86 15116333525. E-mail: liubinjie@188.com; chenjun1222@csu.edu.cn

This work was supported by the clinical medical boot technology innovation project of Hunan Province (2021SK53601, 2021SK53602), the Natural Science Foundation of Hunan Province (2022JJ30871 and 2024JJ5506), the Changsha science and technology plan project (kq2202489), the Research Project on Degree and Postgraduate Education Teaching Reform at Central South University (2024JGB039), and the Young Teacher's Institutional Grant from Xiangya School of Stomatology and Xiangya Stomatological Hospital, Central South University (2019YQ01), P.R. China.

Patients with stage III/IV periodontitis often have anterior teeth with pathological tooth flaring, drifting and elongation. Extraction is frequently the result of periodontally hopeless teeth (PHT)¹; however, patients with stage III/IV periodontitis often have a strong claim to retain their natural teeth, especially young patients. Since Grossman² proposed the concept of intentional replantation (IR) in 1982, it has gradually become the final treatment option for refractory PHT. IR is a minimally invasive method in which PHT are extracted and reimplanted into the primary alveolar socket after root evaluation and removal of inflammatory lesions. A study reported that 48 PHT in 48 patients underwent IR and were followed up for 18 months.³ The overall survival rate at the ninth month was 95.8% and declined to 91.7% at the eighteenth month. The improved rate of mobility was 89.1% at the ninth month and the ankylosis percentage was 77.3% at the eighteenth month. The



survival rate and improved rate of mobility of anterior teeth were both better than those of posterior teeth.^{3,4} However, previous studies have focused on cleaning inflammatory granulation tissue in the alveolar sockets and have not targeted modifications to the shape of the alveolar sockets for reimplantation.^{3,5} This may result in secondary occlusal trauma. The present study is the first to report the clinical effect of dental implant system-assisted IR. The authors evaluated this by recruiting 22 patients with stage III/IV periodontitis (a total of 25 teeth) over the past 7 years to provide new insights into treating PHT of patients with stage III/IV periodontitis.

Materials and methods

Subjects

Patients with stage III/IV periodontitis who visited the present authors' department from June 2015 to June 2022 and who had severe periodontal bone destruction, severe loosening and difficulty achieving preservation with conventional treatment were considered for the study. A total of 22 patients with 25 PHT were included. The inclusion criteria were as follows:

- healthy adults without systemic diseases;
- no history of smoking or areca nut chewing;
- no pregnancy or no breast feeding;
- periodontal pockets were deep to the level of the apical region, and the tooth showed grade III mobility. Radiographs showed that periodontal bone destruction was severe and could not be preserved by conventional treatment;
- patient strongly in favour of retention of the PHT while accepting the risk of having to remove them if the dental implant system-assisted IR treatment fails;
- adjacent teeth could help to fix the replanted teeth (i.e., the movability of the adjacent teeth was less than grade II and the distance was within 2 mm);
- the width of the remaining alveolar bone is greater than that of the root.

The exclusion criteria were as follows:

- PHT is a residual root, residual crown or full-crown restoration;
- PHT has significant occlusal trauma or crowding;
- patient refused to receive treatment or has displayed compliance.

The study was approved by the Ethics Committee of Xiangya Stomatological Hospital, Central South University (ethics no. 20140004). All included subjects were

given full details regarding the treatment procedures and signed informed consent forms.

Treatment procedure

Preoperative preparation

All included PHT patients received non-surgical periodontal therapy and oral hygiene promotion before surgery. Dental implant system-assisted IR was performed 2 months after initial periodontal therapy (Fig 1a).

Surgical procedure

PHT were extracted using a minimally invasive approach after local anaesthesia (Fig 1b and c). One dental practitioner performed subgingival scaling of the adjacent tooth and scratched the extraction pit until the bone surface was exposed (Fig 1d). Another dental practitioner performed root canal therapy (RCT) for the extracted tooth through retrograde filling in vitro and used Iroot SP (Innovative Biocrealmix, Vancouver, Canada) to seal the apex of the tooth (Fig 1e). The dental implant system was employed to determine the direction of implantation (Fig 1f). The root surface of the isolated PHT was scaled to remove calculus and inflammatory granulation tissue and the root profile was trimmed to better match the prepared socket (Fig 1g). The operative area was rinsed with gentamicin (Fig 1h). The prepared implant cavity was selectively filled with an appropriate amount of Bio-Oss spongy bone substitute (Geistlich, Wolhusen, Switzerland) (Fig 1i). The in vitro prepared PHT was re-implanted into the socket and covered the Bio-Gide membrane (Geistlich) (Fig 1j). A periodontal splint was used to fix the reimplanted PHT (Fig 1k), and the occlusion was adjusted to uniform light contact (Fig 1).

Postoperative management

Amoxicillin (0.5 g, tid) and ornidazole (0.5 g, bid, after meals) were taken orally for around 3 to 5 days. Meanwhile, the patient was prescribed with 0.12% chlorhexidine mouthrinse to be used three times a day for 2 weeks. The sutures were removed after 2 weeks. Follow-up visits were conducted at 6 and 12 months after surgery, and annually thereafter.

Follow-up treatment

At each follow-up visit, the patient was given oral hygiene instruction (OHI) and supportive periodontal

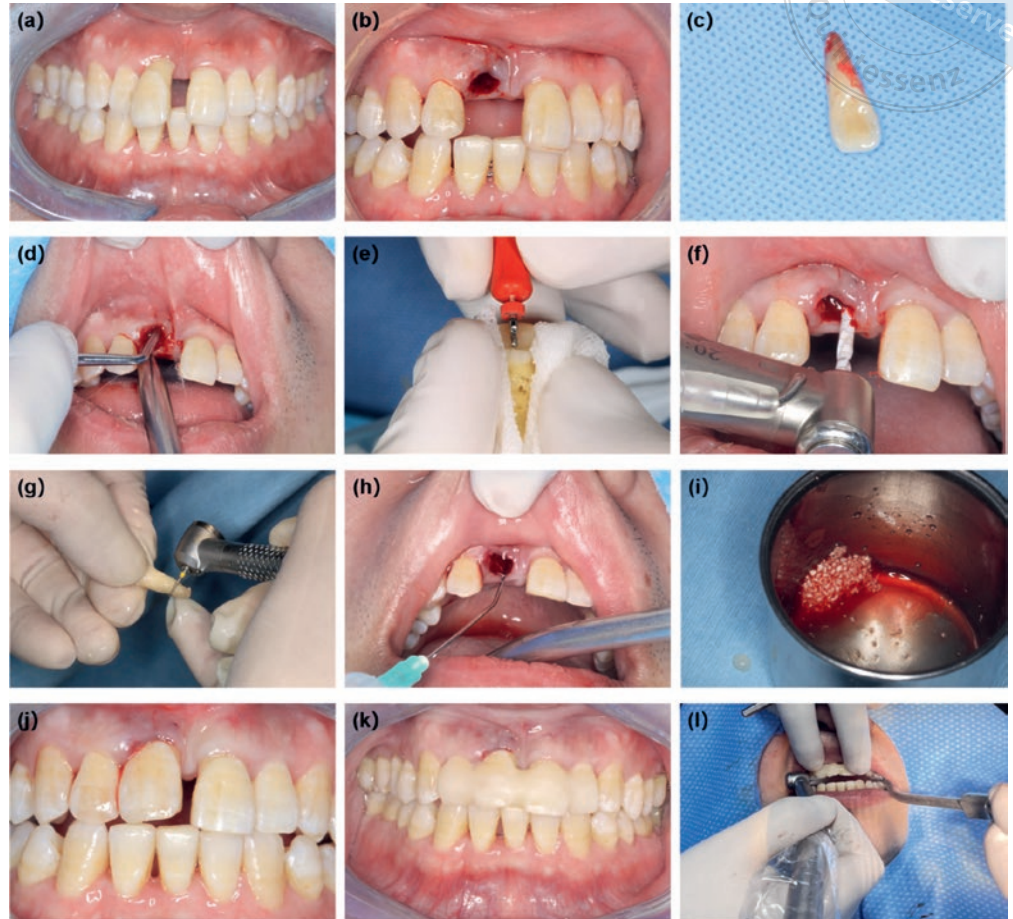


Fig 1 Surgical procedure. Two months after non-surgical periodontal therapy (a). Isolation of the affected PHT (b and c). Scratching the alveolar socket thoroughly (d). RCT for the PHT in vitro (e). Dental implant system-assisted preparation of the alveolar socket (f). High-speed dental handpiece for tooth root shape trimming (g). The alveolar socket was rinsed using gentamicin (h). Implantation of bone powder (i). The PHT prepared in vitro was reimplanted into the socket (j). The PHT was fixed using the periodontal splint (k). Occlusal adjustment to achieve light contact (l).

therapy (SPT). Their occlusal relationship was checked to ensure that the relationship in the operated area was light or no contact. The principle of occlusal adjustment involves a small amount and multiple times.

Observation indicators

The periodontal indicators, including tooth movement, periodontal probing depth (PPD), gingival recession (GR), clinical attachment loss (CAL), Bleeding Index (BI) and horizontal overlap coverage were examined and recorded by the same dental practitioner before surgery, 6 months after surgery and 1 year after surgery. During follow-up, CBCT was used to monitor root resorption and measure the distance from the top of the labial and palatal alveolar ridge to the bone boundary of the enamel. The success criteria were as follows^{6,7}:

- improvement of periodontal clinical indexes (shallow PPD, no bleeding on probing [BOP], no increase in CAL), no fistula, repeated pus overflow, percussion pain, no inflammation or other adverse reactions, and good masticatory function;

- alveolar bone height and density either increased or remained unchanged based on the imaging examination.

The criteria for failure were as follows:

- no improvement of the periodontal clinical indexes, fistula, overflowing pus, percussion pain, etc., and inability to retain the reimplanted PHT;
- imaging examination shows progressive destruction of the alveolar bone;
- poor compliance, repeated fracture of fixation, failure to follow up on schedule, poor inflammation control.

Statistical analysis

SPSS 26.0 software (IBM, Armonk, NY, USA) was used for the statistical analysis. The measurement data were expressed as mean ± standard deviation, and repeated measurement data were used for repeated measures data. The level of statistical significance was set at $P < 0.05$.

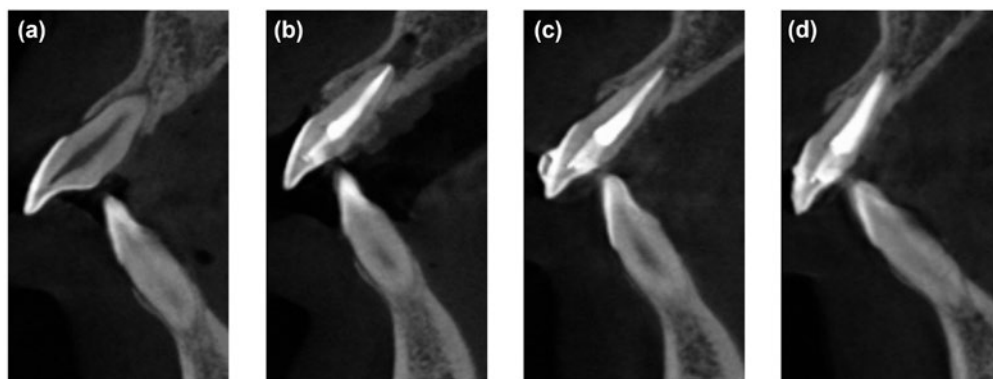


Fig 2 CBCT images before and after dental implant system-assisted IR. Preoperative imaging data (a). Immediate postoperative imaging data (b). Imaging data 6 months after dental implant system-assisted IR (c). Imaging data 1 year after dental implant system-assisted IR (d).

Results

General information

A total of 22 patients (13 men and 9 women) aged 18 to 79 years (mean age 41 years) and 25 PHT with stage III/IV periodontitis met the inclusion. The postoperative follow-up results showed that 22 reimplanted PHT were retained successfully, with a success rate of 88%.

Imaging analysis

Preoperative CBCT showed significant alveolar bone resorption in all PHT, ranging in height from half of the root to one-third of the root apex. Six months after IR, there was no obvious shadow in the root apices of the 22 reimplanted PHT, the density was uniform and the alveolar bone height had recovered to a certain extent. The main mode of healing was tooth ankylosis (Fig 2). A reduced density projection appeared in the apical area 6 months after the IR of one reimplanted PHT. One reimplanted PHT loosened and fell out 4 months after IR, and another loosened and fell out 6 months after surgery.

Periodontal index analysis

All PHT had severe attachment loss before surgery. The looseness of all PHT ranged from degree II to III. A total of 150 sites were found in the 25 PHT, with PPD ranging from 3 to 10 mm. Six to twelve months after surgery, 22 reimplanted PHT had stable periodontal splints, without significant loosening. The periodontal splint of one reimplanted PHT was loose and the PPD was 6 mm, and the dental implant was placed after extraction. Two reimplanted PHT fell out at 4 and 6 months after surgery, respectively. The remaining reimplanted PHT showed significant improvements in PPD, CAL, GR, BI, labial and palatal alveolar bone and coverage at 6 months and

1 year after IR compared with those before IR ($P < 0.05$); however, there was no significant difference between 6 months and 1 year after surgery ($P > 0.05$) (Table 1 and Fig 3).

Discussion

As the economy, society and dental technology have developed, preserving as many natural teeth as possible has become a common goal for dental practitioners and patients. Conventional IR is applied to non-surgical RCT failure, apical microsurgery failure, external root resorption, coronal root fracture, tooth dislocation due to trauma, and anatomical factors such as a malformed lingual sulcus.^{8,9} In the past, PHT caused by severe periodontitis were considered a contraindication to conventional IR¹⁰; however, in recent years, an increasing number of successful cases have been reported. Thus, IR has become the final possibility for preserving PHT. Studies have shown that IR combined with regenerative surgery reduces PPD and BI significantly and improves the preservation rate of PHT^{3,5,8,11,12}; however, these studies focused mainly on the removal of inflammatory granulation tissue in the alveolar socket, and did not make specific modifications to the shape of the alveolar sockets for reimplantation. Stage III/IV periodontitis usually causes PHT to “drift” and “elongate”, with the anterior teeth presenting a deep vertical and horizontal overlap in a false occlusal relationship. If the shape and orientation of the PHT in the alveolar fossa are not altered, this may result in secondary occlusal trauma.

The present study is the first to report the clinical effect of dental implant system-assisted IR. The results showed that the success rate of implant-assisted IR therapy in the treatment for anterior teeth with pathological tooth drifting and elongation in patients with stage III/IV periodontitis was 88%. Most of the reimplanted PHT showed a significant improvement in peri-

Table 1 Statistical analysis of periodontal indexes before and after dental implant system assisted tooth intentional replantation (mean ± standard deviation).

Index	Preoperative	6 months after surgery	1 year after surgery
PD (mm)	6.80 ± 1.56	3.92 ± 1.67	3.41 ± 1.30
CAL (mm)	6.68 ± 1.91	4.08 ± 1.53	3.73 ± 1.20
GR (mm)	3.20 ± 1.00	0.38 ± 0.71	0.18 ± 0.40
BI	4.24	1.13	0.27
Labial alveolar bone loss (mm)	6.58 ± 2.10	4.88 ± 2.02	4.35 ± 1.54
Palatal alveolar bone loss (mm)	8.64 ± 1.93	5.88 ± 1.39	5.56 ± 1.24
Horizontal overlap (mm)	6.92 ± 3.20	3.41 ± 1.30	3.38 ± 1.30

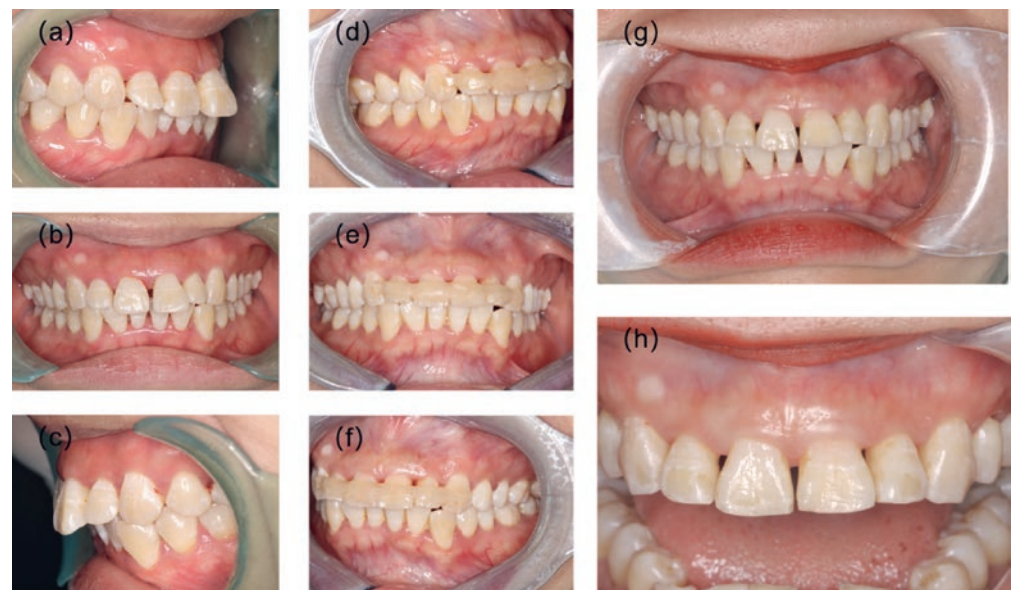

Fig 3 Pre- and postoperative intraoral photographs. Preoperative intraoral photographs (a to c). Intraoral photographs taken 6 months postoperatively (d to f). Intraoral photographs of periodontal splints removed 5 years after surgery (g and h).

odontal indexes after treatment. Imaging data showed a significant increase in alveolar bone height and density. The present study suggested that dental implant system-assisted IR is an effective solution for preserving natural teeth in situations with PHT that have loosened and drifted as a result of stage III/IV periodontitis.

Dental implant system-assisted IR is a multidisciplinary combination of implantation, guided tissue regeneration, RCT and conventional IR techniques. The main advantages of IR are the absence of immune reaction that might lead to rejection of implants, the lack of foreign body sensation, and the fact there is no tooth loss stage. In addition, it can facilitate direct observation of inaccessible areas of the tooth surface, enabling repairs to be performed without damaging adjacent periodontal tissue. It also allows for more visual examination of calculus and inflamed granulation tissue on the surfaces of teeth with stage III/IV periodontitis, facilitating more thorough scaling *in vitro*.⁸ The application of dental implant system-assisted IR

has various advantages. First, stage III/IV periodontitis causes the PHT to drift and elongate, which leads to occlusal trauma. To ensure that the occlusal relationship achieved after IR is light or no contact, the surgeon prepares the cavity with an implant drill based on the alveolar height on the preoperative CBCT scan to more precisely determine the position and orientation of the reimplanted tooth. Second, the dental implant system can re-prepare the shape of the socket according to the shape of the roots so that the reimplanted tooth can better adapt to the alveolar contour, thus improving its stability in the alveolar sockets. Third, bone burns are avoided due to the good cutting performance, hardness, corrosion resistance, and low heat production of the implant drill. Nevertheless, there are still some shortcomings. The choice of implant system is mainly determined by the shape of the patient's teeth and the height of the alveolar bone in order to promote the widespread adoption of implant-assisted IR as a technique for preserving teeth deemed hopeless due to

periodontitis, so it is necessary to establish a replicable and standardised procedure. Although 3D printed surgical guides may be a viable option for achieving this, the present study did not explore this aspect, so it will be examined in future studies.

Conventional IR is mainly for periodontal healthy teeth, requiring the physician to avoid touching the root surface and scraping the socket in order not to damage the periodontal membrane and affect the prognosis¹³; however, for PHT, thoroughly removing the infected periodontium and the inflammatory granulation tissue in the tooth socket to prevent root resorption for replanted teeth is advisable.¹⁴ In the present study, the use of a dental implant system that helped with implant positioning combined with manual scaling was able to completely remove the inflammatory granulation tissue of the alveolar socket to reduce postoperative complications such as root resorption. Furthermore, the conventional IR of tooth displacement caused by other reasons, such as trauma, usually involves a healthy periodontal condition, requiring only 2 to 4 weeks of periodontal fixation to reduce displacement.¹⁵ In vitro studies have shown that the effect of force on periodontal ligament (PDL) fibroblasts (PDLFs) depends on the conditions under which mechanical stimulation is applied. Mechanical stretching increases the proliferation of PDLFs. Thus, mechanical stimulation is required to promote normal healing of PDL tissue and prevent tooth straightening during a certain period of the healing phase¹⁶; however, in the present study, periodontal destruction of the reimplanted PHT was severe. Without fixation, progressive movement is not conducive to periodontal tissue healing and infection control. As such, periodontal splinting was performed on all PHT and the splints were removed after 1 year. When the degree of tooth mobility exceeds Grade I, it is advisable to re-stabilise the loose tooth with adjacent teeth using fibre strips for an additional 3 to 6 months.

Occlusal trauma is a significant promoter of periodontitis.¹⁷ The present analysis of surgical failure suggested that trauma is also one of the major factors that affects the prognosis of dental implant system-assisted IR. Excessive occlusal forces will make it difficult to rebuild the periodontal tissue of the affected PHT, leading to inflammation of the apical area and treatment failure. Thus, dental implant system-assisted IR requires strict and rigorous fixation of loose teeth to ensure a normal occlusal relationship.

There are four main forms of periodontal prognosis for IR in permanent teeth: periodontal healing, surface resorption, replacement resorption and inflammatory resorption.¹⁵ In the present study, the root surface and

alveolar sockets of the PHT were thoroughly debrided intraoperatively. There was almost no normal PDL. Based on the literature and clinical experience, the present authors suspected that implant-assisted IR of PHT may heal in the following way³:

1. Surface resorption: Inflammatory reaction and osteoclast activation may lead to localised dentine resorption. If the resorption is limited to the dentine and does not penetrate the dentinal tubules, then it is self-limiting and can be restored by reattaching new dentine and PDL.^{18,19}
2. Tooth ankylosis and replacement resorption: The periodontium disappears, and the dentine on the root surface fuses with the alveolar bone to replace the root with bone, which is known as tooth ankylosis.²⁰ In severe cases, the root is completely absorbed and replaced by bone tissue in a manner known as replacement resorption, a form of pathological healing that can last from 5 to 20 years, meaning that the reimplanted PHT can remain in the mouth for a considerable period, which may be a special form of site preservation.^{16,21}
3. Inflammatory resorption: If the inflammation is further aggravated after IR, absorption may reach the dentine. The dentine is weak and cannot resist resorption.²² Given that significant periapical inflammation was observed in failed cases, inflammatory resorption may lead to failure of dental implant system-assisted IR. In vivo studies have shown that there are two methods to prevent tooth ankylosis and root resorption in dental IR: the non-cellular method, in which an exogenous substance (such as platelet-derived growth factor) is applied on the root surface or in the alveolar socket, and the cellular method, in which cells (such as PDL-derived cells) are planted on the root surface or placed in the alveolar socket.¹⁶ The specific form of periodontal healing of reimplanted PHT in the present study still needs to be verified by subsequent animal experiments, and this is the focus of the present authors' follow-up research.

Conclusion

The present study preliminarily demonstrated that dental implant system-assisted IR is an effective solution for the retention of anterior teeth with pathological tooth flaring, drifting and elongation in patients with stage III/IV periodontitis. Further animal studies are needed to investigate the healing pattern of the reimplanted PHT and how to promote periodontal ligament healing. Meanwhile, to improve the success rate and predictability of PHT preservation, more potential influencing

factors should be explored, and surgical indications and the prognosis evaluation system should be improved to provide more treatment options for preserving natural teeth.

Conflicts of interest

The authors declare no conflicts of interest related to this study.

Author contribution

Drs Ya Hui QIAO, Xin Yu ZHANG, Bin Jie LIU and Jing Wen CAI designed the study; Drs Ya Hui QIAO, Lin Lin ZHANG and Jun CHEN collected and analysed the data and drafted the manuscript. All authors revised the manuscript and approved the manuscript.

(Received Jun 23, 2023; accepted Jan 18, 2024)

References

- Caton JG, Armitage G, Berglundh T, et al. A new classification scheme for periodontal and peri-implant diseases and conditions - Introduction and key changes from the 1999 classification. *J Clin Periodontol* 2018;45(suppl 20):S1-S8.
- Grossman LI. Intentional replantation of teeth: A clinical evaluation. *J Am Dent Assoc* 1982;104:633-639.
- Zhang J, Luo N, Miao D, Ying X, Chen Y. Intentional replantation of periodontally involved hopeless teeth: A case series study. *Clin Oral Investig* 2020;24:1769-1777.
- Santos JM, Marques JA, Esteves M, Sousa V, Palma PJ, Matos S. Intentional replantation as a starting approach for a multidisciplinary treatment of a mandibular second molar: A case report. *J Clin Med* 2022;11:5111.
- Ong TK, Lim D, Singh M, Fial AV. Factors influencing the treatment outcome of intentional replantation on teeth with periapical periodontitis: A systematic review and meta-analysis. *J Evid Based Dent Pract* 2022;22:101722.
- Peer M. Intentional replantation - A 'last resort' treatment or a conventional treatment procedure? Nine case reports. *Dent Traumatol* 2004;20:48-55.
- Zhang JL, Wang XF, Wang X, et al. Application of intentional replantation in the preservation of teeth to be extracted in severe periodontitis [in Chinese]. *Ningxia Yi Ke Da Xue Xue Bao* 2020;42:1042-1046.
- Plotino G, Abella Sans F, Duggal MS, et al. Present status and future directions: Surgical extrusion, intentional replantation and tooth autotransplantation. *Int Endod J* 2022;55(suppl 3):827-842.
- Chiu YL, Chiang CP, Lee MS, Ho CJ. Intentional replantation - A case report with 20-year follow-up. *J Dent Sci* 2023;18:453-455.
- Nagappa G, Aspalli S, Devanoorkar A, Shetty S, Parab P. Intentional replantation of periodontally compromised hopeless tooth. *J Indian Soc Periodontol* 2013;17:665-669.
- Keceli HG, Hendek MK. Fifteen months follow-up of a hopeless tooth treated with two-step procedure involving intentional replantation and free gingival graft. *Eur J Dent* 2014;8:559-562.
- Cho SY, Lee SJ, Kim E. Clinical outcomes after intentional replantation of periodontally involved teeth. *J Endod* 2017;43:550-555.
- Pisano M, Di Spirito F, Martina S, Sangiovanni G, D'Ambrosio F, Iandolo A. Intentional replantation of single-rooted and multi-rooted teeth: A systematic review. *Healthcare (Basel)* 2022;11:11.
- Lindskog S, Pierce AM, Blomlof L, Hammarstrom L. The role of the necrotic periodontal membrane in cementum resorption and ankylosis. *Endod Dent Traumatol* 1985;1:96-101.
- Fouad AF, Abbott PV, Tsilingaridis G, et al. International Association of Dental Traumatology guidelines for the management of traumatic dental injuries: 2. Avulsion of permanent teeth. *Dent Traumatol* 2020;36:331-342.
- Ideno H, Komatsu K, Nakashima K, Nifuji A. Tooth transplantation and replantation: Biological insights towards therapeutic improvements. *Genesis* 2022;60:e23496.
- Dommsich H, Walter C, Difloe-Geisert JC, Gintaute A, Jepsen S, Zitzmann NU. Efficacy of tooth splinting and occlusal adjustment in patients with periodontitis exhibiting masticatory dysfunction: A systematic review. *J Clin Periodontol* 2022;49(suppl 24):149-166.
- Andreasen JO. Periodontal healing after replantation and autotransplantation of incisors in monkeys. *Int J Oral Surg* 1981;10:54-61.
- Kristerson L, Andreasen JO. Influence of root development on periodontal and pulpal healing after replantation of incisors in monkeys. *Int J Oral Surg* 1984;13:313-323.
- Kotsanos IN, Tzika E, Economides N, Kotsanos N. Intentional replantation and management of avulsion related ankylosis and external cervical resorption. A 10-year follow up case report. *Dent Traumatol* 2023;39:392-398.
- Sapir S, Shapira J. Decoronation for the management of an ankylosed young permanent tooth. *Dent Traumatol* 2008;24:131-135.
- Rumpler M, Würger T, Roschger P, et al. Osteoclasts on bone and dentin in vitro: Mechanism of trail formation and comparison of resorption behavior. *Calcif Tissue Int* 2013;93:526-539.