

## Arch Expansion in Cleft Lip and Palate Children: a Comparison between Rapid Palatal Expansion and Quad Helix Expansion Appliances

Najeeb Abu Rub<sup>1</sup>, Ab Rani Samsudin<sup>1</sup>, Ahmad Burhanuddin<sup>1</sup>, Nizam Abdullah<sup>1</sup>

**Objective:** To compare the arch expansion effect between the Quad Helix (QH) palatal expansion appliance and the rapid palatal expansion (RPE) appliance.

**Methods:** The sample consisted of 27 cleft lip and palate children who required palatal expansion as part of their orthodontic treatment: 13 were treated with the QH and 14 with the RPE. Dental casts were taken before treatment and at the end of the retention period after expansion. Inter-canine width, inter-molar width, and palatal depth were measured in each cast. In addition, occlusal radiographs were obtained before and 2 weeks after expansion to evaluate sutural separation by the appliances.

**Results:** Posterior crossbites were corrected in all patients following expansion. Both the QH and the RPE groups produced significant increases in inter-canine width (2.11 mm and 3.08 mm, respectively) and maxillary inter-molar width (3.49 mm and 4.80 mm, respectively). Neither the QH nor the RPE group demonstrated a significant change in palatal depth (-0.50 mm and -0.46 mm, respectively). The ratio of skeletal change to total expansion was greater in the RPE group (0.30) than that in the QH group (0.18).

**Conclusion:** It was suggested that both the QH and the RPE appliances were capable of expanding the maxillary dentition and alveolar process, and were equally capable of correcting posterior crossbites. RPE was more effective in the midpalatal suture separation.

**Key words:** cleft lip and palate, palatal expansion, quad helix, rapid palatal expansion.

Changes in occlusion and maxillary dental arch dimensions in cleft lip and palate (CLP) patients have attracted the attention of many researchers. CLP children have a constricted maxilla and posterior crossbite, which is believed to be caused by surgical scar tissue after cleft palate closure<sup>1</sup>. Palatal expansion has been controversial for more than 100 years<sup>2</sup>. The arch can be expanded by a combination of skeletal and dental

expansion. Skeletal expansion involves separating the right and the left maxillary halves at the midpalatal suture; dental expansion results from buccal tipping of the maxillary posterior teeth<sup>3-9</sup>. The skeletal or dental effect is dependent on the rate of expansion and the age of the patient during treatment<sup>4</sup>. The goal of palatal expansion is to maximise the skeletal effect and minimise the dental effect, while allowing for physiological suture remodelling after separation<sup>6</sup>.

Maxillary arch expansion is usually carried out at age 7 to 10 years, before bone grafting<sup>10</sup>, which is used to replace missing bone in the cleft alveolus (tooth-bearing bone). Maxillary expansion is usually initiated prior to the ossification of the midpalatal suture. Clinicians

<sup>1</sup> School of Dental Sciences, Health Campus, University Sains Malaysia, Kelantan, Malaysia.

**Corresponding author:** Dr Najeeb Abu Rub, Department of Orthodontics, Prince Fahad Bin Sultan Hospital, P.O. Box 1626, Tabuk, Saudi Arabia. Email: najeeb\_aburub@yahoo.com

interpret the ossification of the palatal suture using appropriate diagnostic aids. Many studies indicate that the optimum time for palatal separation is during the pubertal growth spurt. Once the child completes their pubertal growth spurt, midpalatal suture separation is difficult<sup>9</sup>. This is because as early as 12 to 13 years of age, the midpalatal maxillary suture starts forming bony interdigitations, thereby locking the two maxillary halves together<sup>11</sup>. Spinazze stated in 1997 that maxillary transverse growth significantly sustained comparison with other dimensions. The maxillofacial sutures close at around 14 to 15 years of age in females and 15 to 16 years of age in males<sup>12</sup>.

Expansion appliances include rapid and slow expansion appliances. The rapid palatal expansion (RPE) appliance produces a large force at the suture site over a short period<sup>6,7</sup>.

The large force maximises skeletal separation of the midpalatal suture by devastating the suture before any dental movement or physiological suture adjustment can occur<sup>5,9</sup>. This form of midpalatal suture separation might induce patient discomfort. The RPE appliance requires patient or parent co-operation in appliance activation. Slow expansion appliances, such as the Quad Helix (QH), have been shown to allow for more physiological adjustment to suture separation with less potential for relapse<sup>13</sup>.

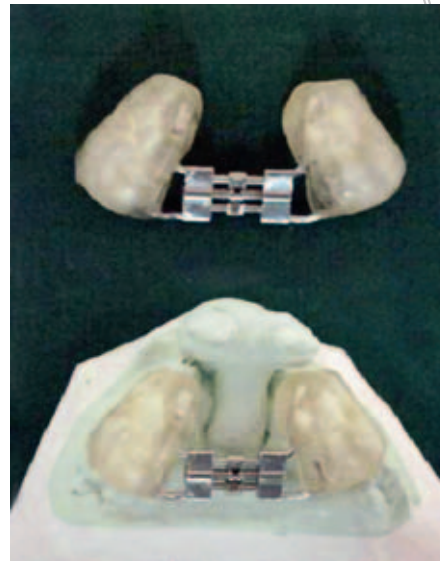The purpose of the present study was to evaluate the arch expansion effect of RPE and QH appliances. The amount of midpalatal suture separation, inter-canine width, inter-molar width and palatal depth change before and after treatment were calculated to elucidate the mechanism of each appliance.

## Material and Methods

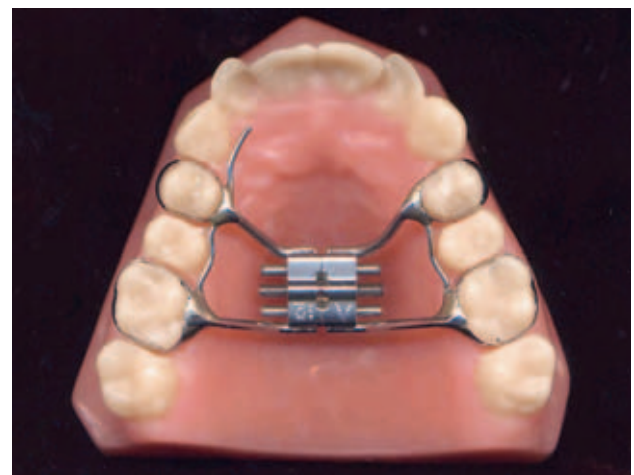
The study sample consisted of 27 cleft lip and palate patients, 14 treated with RPE and 13 with QH appliances, from the Kelantan Combined Cleft Lip and Palate and Craniofacial Deformity Clinic (KCCDC), Malaysia. All patients were selected based on the following criteria: cleft lip and palate patients, in mixed to early permanent dentition, requiring palatal expansion as part of their comprehensive orthodontic treatment.

The RPE sample included 6 boys and 8 girls, with an average age of 11.5 years. Bilateral clefts were found in 8 of 14 RPE patients, the other 6 were unilateral. Twelve of the 14 patients had either a unilateral or a bilateral posterior crossbite at the start of the treatment. The average treatment time was 120 days.

The QH expansion sample included 6 boys and 7 girls with an average age of 10 years. Seven of 13 QH patients



**Fig 1** Hygienic bonded expansion appliance. (A) Model of hygienic bonded expansion appliance. (B) Hygienic bonded expansion appliance placed on cast.

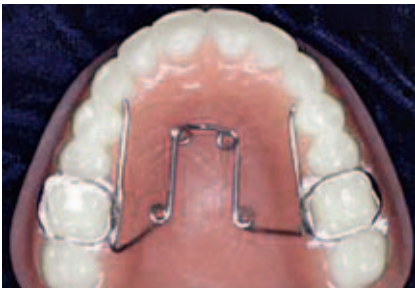

**Fig 2** Banded rapid maxillary expansion.

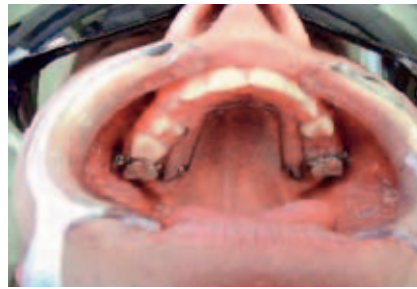had bilateral clefts, and the other 6 patients had unilateral clefts. Twelve of the 13 patients had a unilateral or bilateral posterior crossbite at the start of the treatment. The average treatment time for this group was 160 days.

The RPE appliances are tissue- and tooth-borne or tooth-borne appliances that consist of a midpalatal jackscrew. They can either be banded or bonded to the maxillary anchor teeth (Figs 1 and 2). Several designs of RPE appliances have been reported in the literature, including the banded Hyrax expander, the banded Haas expander, the bonded hygienic expander, and the all-acrylic bonded expander<sup>14</sup>. However, there is no literature documenting the difference in the amount of lateral expansion when using various appliances.

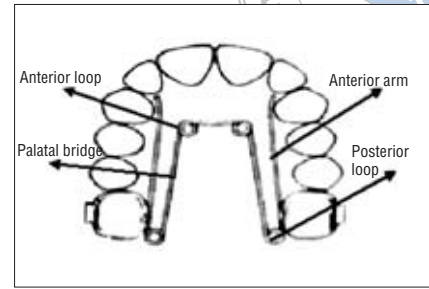
Patients were instructed to activate the jackscrew



**Fig 3** Quad Helix appliance.



**Fig 4** Quad Helix appliance cemented *in situ*.



**Fig 5** Components of Quad Helix.

twice a day, once in the morning and once in the evening, producing approximately 0.5 mm of expansion until the maxillary permanent first molar (or the primary second molar) palatal cusps were in contact with the mandibular buccal cusps, or judged satisfactory by the clinician. Overcorrection was considered to compensate for relapse following expansion<sup>15</sup>. The expansion appliances were left in place passively for an additional 3 months for retention. In some cases this was followed by fixed arch-wire treatment for retention.

The QH was pre-adjusted and cemented in place on the first molars, and there was no need for reactivation in most cases (Figs 3 and 4). The QH consisted of four loops or helices, two anterior and two posterior (Fig 5). The portion of wire between the two anterior helices is called the anterior bridge. The wire connecting the anterior and posterior helices on each side is called the palatal bridge. The outer arm on each side of the QH extended anteriorly from the posterior loop to a free end, which rested against the lingual surface of the posterior teeth. The four helices incorporated in the appliance were intended to increase the wire length, and therefore increase the flexibility and active range of the appliance. The appliance was fabricated from 0.965 mm wire soldered to bands on the permanent first molars. It was checked regularly to ensure that the wires did not impinge on the palatal tissue as expansion progressed. The QH was pre-activated by stretching the two molar bands

apart prior to cementation (Fig 6). The QH was invisible since it fitted behind the teeth, and the patients quickly adapted to wearing it within a week. During the following 4 months of expansion, the appliances were checked monthly. Adequate expansion was considered achieved once maxillary permanent first molar palatal cusps were in contact with the mandibular buccal cusp. The QH appliances were left in place passively for an additional 3 months for retention.

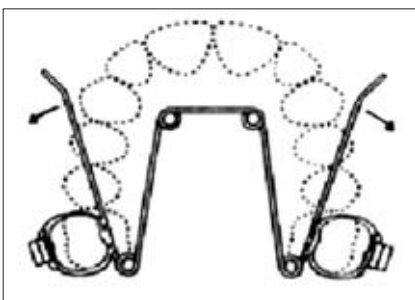
*Study cast measurement*

The pre- and post-treatment orthodontic study models were used for calculation of comparative changes in inter-canine width, inter-molar width and palatal depth. The anatomical and constructed points for measurement were determined according to Sillman<sup>16</sup>.

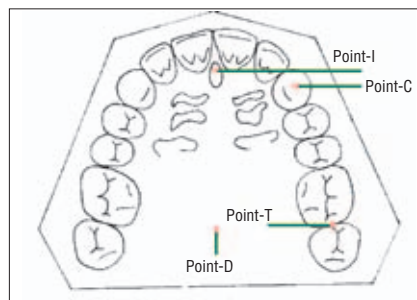
Anatomical and constructed points digitised on the dental casts

Certain anatomical landmarks were identified on the pre- and post-treatment dental casts (Fig 7). The identified landmarks were as follows:

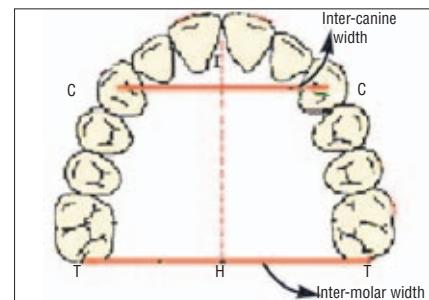
- I-point (incisal point): point on the top of the alveolar crest where the incisive papilla and labial frenum meet, or the tip of the interdental papilla between the central incisors.
- C-point (cuspid point): point on the lateral sulcus



**Fig 6** Initial activation of Quad Helix before insertion.



**Fig 7** Anatomical and constructed points digitise on the dental casts.



**Fig 8** Distance measurement.

crossing the crest of the alveolar ridge, or the distal anatomical contact point of the canine.

- T-point (tuberosity point): the posterior limit of the maxillary tuberosity in the sulcus where the pterygomandibular raphe adheres, or the distal point of the second primary molar or first permanent molar.
- D-point (palatal depth point): the deepest palatal point where it coincides with T-T points at the cross-junction point H.


#### Distances measurement methods

The following distances were measured on the pre- and post-treatment dental casts using a digital sliding caliper (Fowler Ultra-Gold, OH, USA), and the results were entered into SPSS version 11.0 for analysis.

- C-C: Inter-canine width, or palatal anterior arch width. To compare the inter-canine palatal width change, C-C points in the pre- and post-treatment casts were measured (Fig 8) using the digital sliding caliper.
- T-T: Inter-tuberosity width (inter-molar width or palatal posterior arch width). To compare the inter-tuberosity palatal width change, T-T points in the pre- and post-treatment casts were measured using the digital sliding caliper (Fig 8).
- H-D: Palatal depth. Palatal depth was measured using a square sheet of hard clear acrylic (2 mm thick) and a rectangular orthodontic wire (0.06 mm diameter). A straight line was drawn on the clear acrylic and a hole was made in the centre. The clear acrylic was placed on the occlusal surfaces of the teeth where the line coincides with T-T points. The orthodontic wire was inserted into the hole downwards to touch point D. A mark (H) was made at the entry point of the wire before it was removed. The length of the wire H-D was measured using the digital sliding caliper to determine the palatal depth (Fig 9).

#### *Radiographic evaluation*

Maxillary occlusal radiographs were obtained before treatment and 2 weeks after active expansion. The radiographs were performed with the maxillary occlusal plane parallel to the floor and the x-ray cone positioned at a 60-degree angle to the film and parallel to the patient's facial midline. Pre- and post-treatment radiographs were reviewed for evaluation of the sutural opening. Evidence



**Fig 9** Method for measuring the palatal depth.

of suture expansion was demonstrated by the radiolucent widening of the suture<sup>17</sup>.

#### *Statistical analysis*

The statistical analysis was carried out using Statistical Package for the Social Sciences (SPSS v.11.0, Chicago, IL, USA). Significant changes in the distances of inter-canine width, inter-tuberosity width and palatal depth on pre- and post-treatment models in both the expansion groups were evaluated using paired *t*-test and Wilcoxon signed ranks test. The level of significance was set at  $P < 0.05$ .

The correlation of the palatal changes with age was also tested for both expansion groups using the non-parametric test, Spearman's rank correlation. The value of Spearman's correlation coefficients (SCC) varied from -1 to 1 (inclusive, without units). The correlation was significant at  $P < 0.05$ .

The range of values was as follows:

- SCC = 1: perfect positive correlation
- $0 < \text{SCC} < 1$ : positive but not perfect correlation
- SCC = 0: no correlation
- $-1 < \text{SCC} < 0$ : negative but not perfect correlation
- SCC = -1: perfect negative correlation.

Comparison of the palatal changes between RPE and QH was performed. No statistical comparison was performed because of the differences in the amount of expansion in the two groups.

#### *Reliability of the measurements*

To assess the reliability of the measurements, all measurements (inter-canine width [C-C], inter-tuberosity width [T-T] and palatal depth [H-D]) were completed twice on 10 sets of casts (5 QH casts and 5 RPE casts) with two weeks' interval. Paired *t*-tests showed the differences

were not statistically significant ( $P > 0.05$ ) between repeated measurements for any of the measurements.

The degree of reliability of measurements, i.e. intra-class correlation coefficient (ICC) was calculated. All ICC were close to 1.00, which suggested that the measurements were almost identical and there were negligible errors of measurement.

## Results

Lateral dental and dentoalveolar width significantly increased in both groups. Posterior crossbites were corrected in all patients following expansion.

Table 2 shows the treatment changes in the RPE group. There were significant increases of 3.08 mm in the inter-canine width and 4.80 mm in the inter-molar width. No change was observed in palatal depth (-0.460 mm). Table 3 shows the treatment changes in the QH group. Significant increases were observed in inter-canine width (2.11 mm) and inter-molar width (3.49 mm), but not in palatal depth (-0.50 mm). Table 4 shows the changes between the RPE and the QH groups. Statistical analysis was not performed for these data because of the differences in the amount of expansion in the two groups. Both the QH and the RPE groups produced significant increases in inter-canine width (2.11 mm and 3.08 mm, respectively) and maxillary inter-molar width (3.49 mm and 4.80 mm, respectively). Neither the QH nor the RPE groups demonstrated a significant change in palatal depth (-0.50 mm and -0.46 mm, respectively). The ratio of skeletal change to total expansion was greater in the RPE group (0.30) than that in the QH group (0.18).

Table 5 shows the SCC for changes in the QH group. The correlation was found to be not significant. Table 6 shows the SCC for changes in the RPE group. Inter-canine width change demonstrated a significant positive correlation with inter-molar width change (SCC = 0.65). No correlation was found between age and any of the variables in the both the groups (Tables 5 and 6).

In the analysis of occlusal radiographs, all the 13 patients in the RPE group had occlusal radiographs available for evaluation, and opening of the midpalatal suture was demonstrated in all (100%). Twelve of the 14 patients in QH group had occlusal radiographs available for evaluation, and opening of the midpalatal suture was demonstrated in 9 patients (75%); the other 3 patients showed no evidence of suture opening (25%).

## Discussion

One of the limitations of this study was the failure to match the age and gender of the groups. The age differ-

ence between the groups could make a difference to the relative effect of expansion therapy. Furthermore, both bonded and banded RPE appliances were included in the sample, but the acrylic coverage of the bonded appliance might alter the occlusal force and attachment style.

The change in inter-molar width reflected the total amount of lateral dental and dentoalveolar expansion, and significantly increased in both groups. Posterior crossbites were corrected in all patients following expansion. Similar results have been reported using slow or rapid expansion appliances<sup>18,19</sup>. da Silva Filho et al<sup>19</sup> evaluated the effect of RPE for 32 children between 5 and 11 years of age, by antero-posterior radiographs. Results confirmed previously reported data that the triangular opening in the anterior alveolar area was greater than in other parts of the midpalatal suture. It is believed that with expansion there is an orthodontic effect, even at an early age<sup>3</sup>.

Inter-canine width change, which approximates the amount of midpalatal suture separation, increased significantly in both the RPE (1.41 mm) and QH (0.99 mm) groups. Sandikcioglu and Hazar<sup>20</sup> compared the effect of three different expansion methods in mixed dentition, evaluated by cephalometric films and dental casts: removable plate for semi-rapid palatal expansion, QH appliance for slow maxillary expansion, and conventional fixed Hyrax appliance for RPE. It was concluded that greater skeletal expansion and increase in inter-canine width were provided by the RPE appliance, followed by the removable appliance, and least by QH.

The percentage of inter-canine width to inter-molar width change was calculated, and was greater in the RPE group (30%) than in the QH group (18%). This was similar to previous studies that reported a higher suture separation rate (40 to 58%) with RPE appliances<sup>4,19</sup>, and a lower suture expansion rate (16 to 40%) with slow expansion appliances<sup>4,20</sup>.

RPE appliances generate a greater force<sup>21</sup>, as much as 2 to 5 kg per activation<sup>6,9</sup>. QH expansion appliances generate around 400 g of force<sup>22</sup>, which might be insufficient to separate a progressively mature suture. However, an animal study using the slow-expansion appliance reported an orthopaedic effect comparable to that of RPE appliances<sup>23</sup>. Ladner and Muhl<sup>4</sup> examined 60 maxillary expansion cases, 30 cases were with RPE and 30 with QH appliances. Although both groups demonstrated similar amounts of maxillary dental expansion, the RPE group had greater average skeletal expansion.

Palatal depth change resulting from expansion has been reported to occur because of the lowering of the palatal shelves of the maxilla<sup>24</sup>, or a change in dentoalveolar height<sup>4</sup>. Previous studies on palatal depth

**Table 1 Reliability of measurements**

Measurement (mm)	Mean (SD)	95% Confidence interval of the difference		<i>t</i> statistic	<i>P</i> value	ICC
		Lower	Upper			
C-C width	-0.023 (0.061)	-0.050	0.002	-1.850	0.078	0.999
T-T width	0.026 (0.086)	-0.011	0.063	1.447	0.162	0.999
I-H length	0.042 (0.150)	-0.022	0.107	1.344	0.193	0.998

**Table 2 Palatal changes in RPE group (n = 14)**

Measurement (mm)	Pre treatment Median (IQR)	Post treatment Median (IQR)	Difference Median (IQR)	Z statistic <sup>a</sup>	<i>P</i> value
C-C width	26.830 (5.900)	28.940 (7.520)	2.110 (2.640)	-1.334	0.018
T-T width	46.090 (8.070)	49.970 (8.520)	3.490 (2.340)	-2.701	0.007
H-D	17.140 (5.420)	15.600 (3.200)	-0.500 (1.620)	-1.867	0.062

a. Wilcoxon signed ranks.

**Table 3 Palatal changes in QH group (n = 13)**

Measurement (mm)	Pre treatment Median (IQR)	Post treatment Median (IQR)	Difference Median (IQR)	Z statistic <sup>a</sup>	<i>P</i> value
C-C width	26.830 (5.900)	28.940 (7.520)	2.110 (2.640)	-1.334	0.018
T-T width	46.090 (8.070)	49.970 (8.520)	3.490 (2.340)	-2.701	0.007
H-D	17.140 (5.420)	15.600 (3.200)	-0.500 (1.620)	-1.867	0.062

a. Wilcoxon signed ranks.

**Table 4 Comparison of changes between the QH group and the RPE group**

Measurement	Quad Helix		RPE	
	Mean	SD	Mean	SD
ICWC (mm)	2.11	2.64	3.08	3.01
IMWC (mm)	3.49	2.34	4.80	3.98
Ratio ICWC/IMWC	0.18	0.10	0.30	0.19
PDC (mm)	-0.50	1.62	-0.46	1.032

ICWC, inter-canine width change; IMWC, inter-molar width change; PDC, palatal depth change.

**Table 5 Correlation between various palatal changes in QH appliance**

	ICW	IMW	PD	Age
ICW	1.00			
IMW	0.41	1.00		
PD	-0.47	-0.13	1.00	
Age	-0.17	-0.17	-0.18	1.00

ICWC, inter-canine width change; IMWC, inter-molar width change; PDC, palatal depth change.

**Table 6 Correlation between various palatal changes in RPE appliance**

	ICWC	IMWC	PDC	Age
ICWC	1.00			
IMWC	0.65*	1.00		
PDC	0.18	-0.25	1.00	
Age	0.20	-0.142	-0.26	1.00

\*Spearman's rank correlation is significant (*P* value < 0.05)  
ICWC, inter-canine width change; IMWC, inter-molar width change; PDC, palatal depth change.

change showed some variability. O'Higgins and Lee<sup>25</sup> reported a decrease in palatal depth caused by a lowering of the palatal shelves after expansion. Ladner and Muhl<sup>4</sup> demonstrated an increase in palatal depth in both rapid and slow palatal expansion, which was attributable to the eruption of the dentition. Other studies have shown no significant change in palatal depth after expansion<sup>26</sup>. In the present study, no change in palatal depth was found in either group. It is possible that an increase in dentoalveolar height and a lowering of the palatal shelves offset one another and resulted in no change in palatal depth.

For the RPE group, inter-canine width change was a significant factor in the change of the inter-molar width. It is possible that as the total amount of expansion increases, midpalatal suture separation also increases.

Radiographs were evaluated and showed opening of the midpalatal suture in 100% of the RPE group and 75% in the QH group, suggesting that QH expansion produced a less obvious radiographic separation of the midpalatal suture compared with RPE.

Laptook<sup>27</sup> showed that RPE could aid in hearing because it improves the normal function of the pharyngeal ostea of the Eustachian tube by the influence of RPE on the palatal and naso-pharyngeal tissues, especially in CLP<sup>27</sup>.

Midpalatal suture ossification can occur from age 15<sup>28</sup> to age 27<sup>29</sup>, but the optimal period for performing the RPE procedure is considered between 8 and 15 years of age<sup>30</sup>.

## Conclusions

The effects of two types of maxillary expansion appliances were compared in CLP patients. Both the RPE and the QH appliances were capable of expanding the maxillary dentition and alveolar process. Radiographic evidence of midpalatal suture separation was less obvious in the QH than in the RPE group.

## References

- Sakamoto T, Sakamoto S, Harazaki M, Isshiki Y, Yamaguchi H. Orthodontic treatment for jaw deformities in cleft lip and palate patients with the combined use of an external-expansion arch and a facial mask. *Bull Tokyo Dent Coll* 2002;43:223-229.
- Schiffman PH, Tuncay OC. Maxillary expansion: a meta analysis. *Clin Orthod Res* 2001;4:86-96.
- Graber TM and Vanarsdall RL. Orthodontic current principles and techniques. 3rd edition. Missouri: Mosby, 2000.
- Ladner PT, Muhl ZF. Changes concurrent with orthodontic treatment when maxillary expansion is a primary goal. *Am J Orthod Dentofacial Orthop* 1995;108:184-193.
- Haas AJ. Palatal expansion: just the beginning of dentofacial orthopedics. *Am J Orthod* 1970;57:219-255.
- Issacson RJ, Ingram AH. Forces produced by rapid maxillary expansion, II: forces present during treatment. *Angle Orthod* 1964;34:261-270.
- Zimring JF, Issacson RJ. Forces produced by rapid maxillary expansion, III: forces present during retention. *Angle Orthod* 1965;35:178-186.
- Bishara SE, Staley RN. Maxillary expansion: clinical implications. *Am J Orthod Dentofacial Orthop* 1987;91:3-14.
- Wertz RA. Skeletal and dental changes accompanying rapid midpalatal suture opening. *Am J Orthod* 1970;58:41-66.
- Aizenbud D, Hefer T, Rachmiel A, Figueroa AA, Joachims HZ, Laufer D. A possible otological complication due to maxillary expansion in a cleft lip and palate patient. *Cleft Palate Craniofac J* 2000;37:416-420.
- Melsen B. Palatal growth studied on human autopsy material. A histological microradiographic study. *Am J Orthod* 1975;68:42-54.
- Spinazze RP. Surgically assisted rapid palatal expansion. Chicago: University of Illinois, 1997.
- Turley PK. Managing the developing class III malocclusion with palatal expansion and facemask therapy. *Am J Orthod Dentofacial Orthop* 2002;122:349-352.
- Giancotti A, Maselli A, Di Girolamo R. Rapid palatal expansion in treatment of class II malocclusions. *Br J Orthod* 1999;26:179-190.
- Spillane LM, McNamara JA Jr. Maxillary adaptation to expansion in the mixed dentition. *Semin Orthod* 1995;1:176-187.
- Sillman JH. Dimensional changes of the dental arches: longitudinal study from birth to 25 years. *Am J Orthod* 1964;50:824-842.
- Harberson VA, Myers DR. Midpalatal suture opening during functional posterior cross-bite correction. *Am J Orthod* 1978;74:310-313.
- Harrison JE, Ashby D. Orthodontic treatment for posterior crossbites. *Cochrane Database Syst Rev* 2006;1:CD000979.
- da Silva Filho OG, Montes LA, Torelly LF. Rapid maxillary expansion in the deciduous and mixed dentition evaluated through postero-anterior cephalometric analysis. *Am J Orthod Dentofacial Orthop* 1995;107:268-275.
- Sandikcioglu M, Hazar S. Skeletal and dental changes after maxillary expansion in the mixed dentition. *Am J Orthod Dentofacial Orthop* 1997;111:321-327.
- Ioannidou J, Kolokitha O. Rapid maxillary expansion: presentation of 3 clinical cases. *Orthod Fr* 2000;71:95-103.
- McNally MR, Spary DJ, Rock WPI. A randomized controlled trial comparing the quadhelix and the expansion arch for the correction of crossbite. *J Orthod* 2005;32:29-35.
- Ohshima O. Effect of lateral expansion force on the maxillary structure in *Cynomolgus* monkey. *Osaka Dental Univ* 1972;6:11-50.
- Romero M, Latham R, Romance A, Salvan R. Treatment of infant with a rare cleft resolved with use of an orthopedic appliance. *Cleft Palate Craniofac J* 2003;40:642-644.
- O'Higgins EA, Lee RT. How much space is created from expansion or premolar extraction? *Br J Orthod* 2000;27:11-13.
- Davis WM, Kronman JH. Anatomical changes induced by splitting of the midpalatal suture. *Angle Orthod* 1969;39:126-132.
- Laptook T. Conductive hearing loss and rapid maxillary expansion. Report of a case. *Am J Orthod* 1981;80:325-331.
- Bjork A, Skieller V. Growth in width of the maxilla studied by the implant method. *Scand J Plast Reconstr Surgery* 1974;8:26-33.
- Persson M, Thilander B. Palatal suture closure in man from 15 to 35 years of age. *Am J Orthod* 1977;72:42-52.
- Haas AJ. Long-term post-treatment evaluation of rapid palatal expansion. *Angle Orthod* 1980;50:189-217.