

Fibre-reinforced Composite in Clinical Dentistry

Sufyan K. Garoushi¹, Lippo V.J. Lassila¹, Pekka K. Vallittu¹

Abstract: *The use of fibre-reinforced composite (FRC) technology in clinical dentistry may solve many of the problems associated with a metal alloy substructure such as corrosion, toxicity, complexity of fabrication, high cost and aesthetic limitation. There are societies where the use of FRC has become common such as in the U.S., Finland, Belgium and the Netherlands. However, the widespread use of this material is still limited. This article briefly presents background and clinical applications of FRC in dentistry.*

Nowadays, particulate filler composite resin (PFC) enables the clinician to cover a much larger spectrum of indications than a few years ago. The ability to bond PFC to tooth enamel and dentine makes it a desired material to use. Among other things, this is due to substantial improvements in the physical parameters of PFC, in particular their enhanced wear-resistance, strength and colour stability. However, the development of fibre-reinforced composite (FRC) has given the practitioner the first real opportunity to create reliable composite structures. The parameter that has been developed to its maximum potential within classic composites is flexural strength. FRCs have highly favourable mechanical properties, and their strength to weight ratios are superior to those of most alloys. When compared with metal alloys, FRCs offer many other advantages as well including non-corrosiveness, translucency, good bonding properties and repair facility. Additionally, FRCs give alternatives for both office and laboratory fabrication. Therefore it is not surprising that fibre-reinforced composites have the potential for use in many applications in dentistry such as periodontal splinting, orthodontic retention, fibre-reinforced post crowns, reinforcement and repair of a removable dentures as well as of fixed prostheses^{1,2}.

FRC for dental applications has been discussed in the literature since the early 1960s. Since then it took almost

30 years before dental FRCs were applied in clinical use. FRCs are structural materials that have at least two distinct constituents. The reinforcing component provides strength and stiffness, while the surrounding matrix supports the reinforcement and provides workability (Fig 1). The polymer matrix also protects the fibres from the effect of mechanical damage and moisture³.

FRCs can be divided according to the reinforcement and polymer matrices used. Glass fibres are the most commonly used reinforcing fibre in dental applications. Carbon/graphite, aramid, boron and metal fibres are also used⁴⁻⁶. FRCs can also be divided into groups based on fibre length and orientation. Long fibres containing FRCs are called continuous FRCs, but there are also




Fig 1 Unidirectional semi-interpenetrating polymer network resin impregnated fibre-reinforced composite.

¹ Department of Prosthetic Dentistry and Biomaterials Science, Institute of Dentistry, University of Turku, Turku, Finland

Corresponding author: Dr Sufyan K. Garoushi, Department of Prosthetic Dentistry and Biomaterials Science, Institute of Dentistry, University of Turku, Lemminkäisenkatu 2, FI-20520 Turku, Finland. Tel: 358-2-333-83-57; Fax: 358-2-333-83-90; E-mail: sufgar@utu.fi

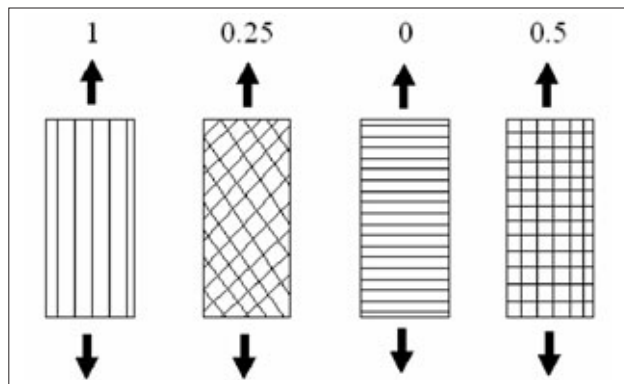
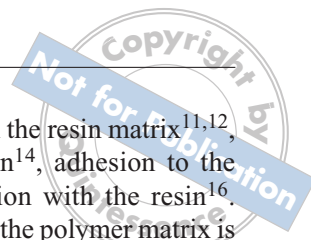


Fig 2 Reinforcing efficiency (Krenchel's factor) (left to right): unidirectional fibres in the direction of the load (0 degrees), bidirectional fibres 45 degrees to the load, unidirectional fibres 90 degrees to the direction of the load, bidirectional fibres 0 and 90 degrees in the direction of the load.

short FRCs. The two main structural types of FRC products presently available are continuous unidirectional and bidirectional fibres (weaves). Unidirectional fibres give anisotropic mechanical properties to the composite and are suitable for applications where the highest stress is known. Reinforcing efficiency (Krenchel's factor⁷) of unidirectional fibres is theoretically 100%, which means that reinforcing properties can be obtained in one direction³. Woven fibres, on the other hand, have an equally reinforcing effect in two directions (orthotropic). The theoretical reinforcing efficiency of such fibres is 50% or 25% according to Krenchel's factor (Fig 2). They are especially suitable in cases where the direction of the load is unknown or where there is no space for unidirectional fibres. If the fibres are orientated randomly as in short fibres, the mechanical properties are equal in all directions and are three-dimensionally isotropic.

Glass fibres have documented reinforcing efficiency and good aesthetic qualities compared with carbon or aramid fibres⁸⁻¹⁰. The effectiveness of fibre reinforcement is dependent on many variables including the type of

resin used, the quantity of fibres in the resin matrix^{11,12}, fibre length¹², form¹³, orientation¹⁴, adhesion to the polymer matrix¹⁵ and impregnation with the resin¹⁶. Adequate adhesion of the fibres to the polymer matrix is one of the important requirements for the strength of the composite^{3,15}. The chemical bond between the polymer and the fibres should ideally be of a covalent nature. Proper adhesion makes it possible to transfer the stresses from the matrix to the fibres. Silane coupling agents have been used successfully to improve the adhesion between the polymer matrix and glass fibres⁹. Laboratory studies on the mechanical properties of FRCs confirm that the improved fibre composite materials currently available, used in combination with conventional veneered materials, set up on equal level with metal-ceramic, and all-ceramic systems¹⁷. Mechanical advantages provided by FRCs are their flexural strength, fatigue strength, elastic modulus and bond strength (of fibre frame to composites and resin cements). Additionally, FRCs are metal free, aesthetic and allow minimally invasive treatment techniques to be used. However, until recently, FRCs did not meet wide clinical acceptance, even though they successfully reinforce long-term restorations like crowns and bridges^{18,19}. The first issue was the sensitive technique of using fibre bundles, and secondly, the mechanical properties were well below the theoretical expectation. This was due to the low fibre content in the definitive appliance as well as due to the inadequate impregnation of the fibres with the resin²⁰. To establish an improved technique, some manufacturers have produced machine-impregnated FRC materials (Table 1). Moreover, one manufacturer (StickTech, Turku, Finland) has used a polymethyl methacrylate (PMMA)-based semi-interpenetrating polymer network (semi-IPN) matrix²¹. Clinically this means that the surface of the fibre structure can be reactivated in order to be bonded reliably when cementing laboratory-manufactured restorations to teeth, cementing root canal posts, layering composite on a fibre structure or repair-

Table 1 Flexural properties of some FRC products

Product	Flexural modulus (GPa)	Flexural strength (MPa)	Manufacturer
everStick® (p)	24.3	764	StickTech, Turku, Finland
FibreKor® (p)	28.3	539	Pentron, Wallingford, Connecticut, USA
Vectris® (p)	28.9	614	Ivoclar Vivadent, Germany
GlasSpan® (n)	13.9	321	Glas Span, Exton, Pennsylvania, USA
Construct (n)	8.3	222	SDS/Kerr, Orange, California, USA
Ribbon® (n)	3.9	206	Ribbon, Seattle, Washington, USA

FRC: fibre-reinforced composite; (p): machine-impregnated by manufacturer; (n): required hand impregnation by the technician or dentist

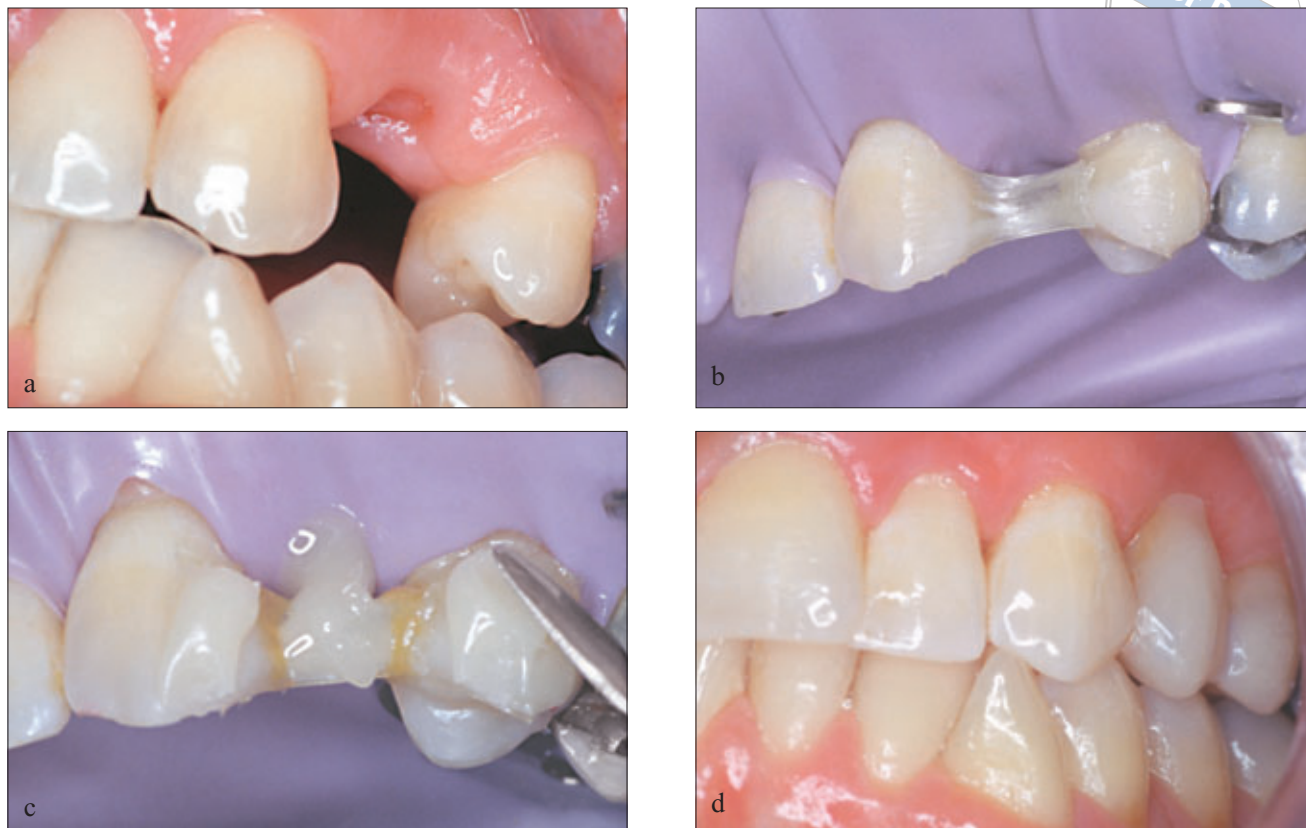

Fig 3 A micro-invasive fibre-reinforced bridge by direct technique: (a) patient with missing maxillary left first premolar; (b) surface retained fibre frame; (c) starting the composite veneer in the pontic area; (d) lateral view of the finished bridge.

ing fibre-reinforced restorations. In addition, the handling properties of FRCs can be improved.

Clinical Cases of FRC Applications

A micro-invasive fibre-reinforced bridge by direct technique

Professor Vallittu, Finland

The patient is a 33-year-old female who lost the first premolar probably because of trauma. The fabrication of a traditional bridge was contraindicated due to the

patient’s young age and intact neighbouring teeth. The missing tooth was to be replaced with an implant crown later on. As replacing the missing tooth quickly was important to patient’s appearance, a micro-invasive bridge with direct technique was prepared using pre-impregnated unidirectional FRC and veneering composite. The adjacent teeth remained free of any preparation during the dynamic treatment approach. Consequently, other treatment methods could be obtained later on, if necessary. The treatment was completed during one visit to the dentist. Prior to the treatment, the occlusion was balanced (Fig 3).

Table 2 Case selection for fibre-reinforced prostheses

Indications	Relative contraindications
<ul style="list-style-type: none"> • Patients who desire an optimal aesthetic result • Patients who require or desire a metal-free prosthesis • Cases in which ease of fabrication in the laboratory is desired • Patients in whom it is desirable to decrease wear on opposing teeth • Patients in whom it is desirable to use an adhesive luting technique • Patients who have dentition with an unknown prognosis 	<ul style="list-style-type: none"> • Patients in whom it is impossible to maintain fluid control • Patients with parafunctional habits • Patients who abuse alcohol • Patients with poor oral hygiene

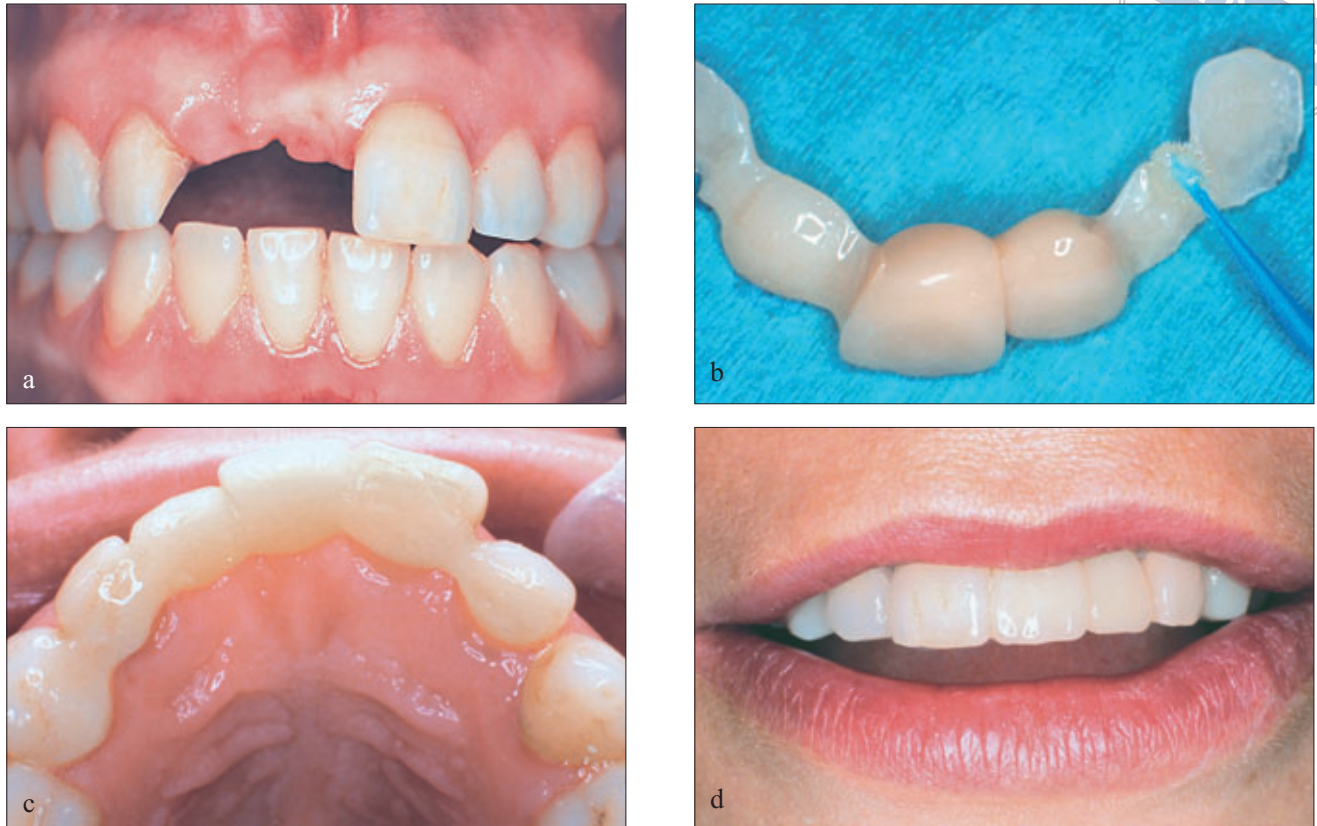

Fig 4 A laboratory fabricated bridge in the anterior area: (a) the situation after the old resin-bonded prosthesis had been removed; (b) dissolving of the cementation surfaces (with resin for 5 minutes before cementation); (c) cementation stage using dual or chemical cure cement; (d) labial view showing excellent colour match.

A laboratory fabricated bridge in the anterior area

Professor Vallittu, Finland

This case represents the replacement of an old metal frame (resin-bonded prosthesis) with a bridge made of FRC. Because of the flexural property of FRC frameworks, the new laboratory made the FRC bridge fit excellently (Fig 4). There are several indications for selecting FRC prostheses and they are summarised in Table 2.

Unlike traditional porcelain-fused-to-metal (PFM) bridges or full-ceramic bridges, FRC prostheses do not require extensive tooth preparation. FRC prostheses allow for the use of different retainer types – even in the same bridge. For example, it is possible to create space for the retainer by removing an old filling or to make completely surface-retained restorations. Surface-retained, inlay, onlay and full-cover crown retainers can all be used. For the clinical situation, a hybrid fixed prosthesis can be prepared by integrating the retainer types onto the same prosthetic structure. An FRC prosthesis combines the best characteristics of the FRC (strength

and rigidity) with those of PFM (wear resistance and aesthetics), providing an alternative to all-ceramic or PFM restorations. Based on current clinical results, it is reasonable to expect FRC fixed partial dentures (FPD) to last 5 years^{18,19,22,23}. However, it should be emphasised that FRC prostheses with a veneering composite offer an alternative, but not a substitute for PFM or full-ceramic prosthetic structures.

Root canal anchoring in combination with surface-retained splinting

Professor Vallittu, Finland

A 57-year-old woman was referred for the treatment of a damaged maxillary lateral incisor. Due to the weak root of the tooth, an individually formed fibre post system was used. The medical history of the patient revealed relatively heavy bruxism, which had weakened the periodontal support of the maxillary anterior teeth. To give additional support for the anterior region, a non-destructive surface-retained periodontal splint was combined with the root canal post system. The splinting was

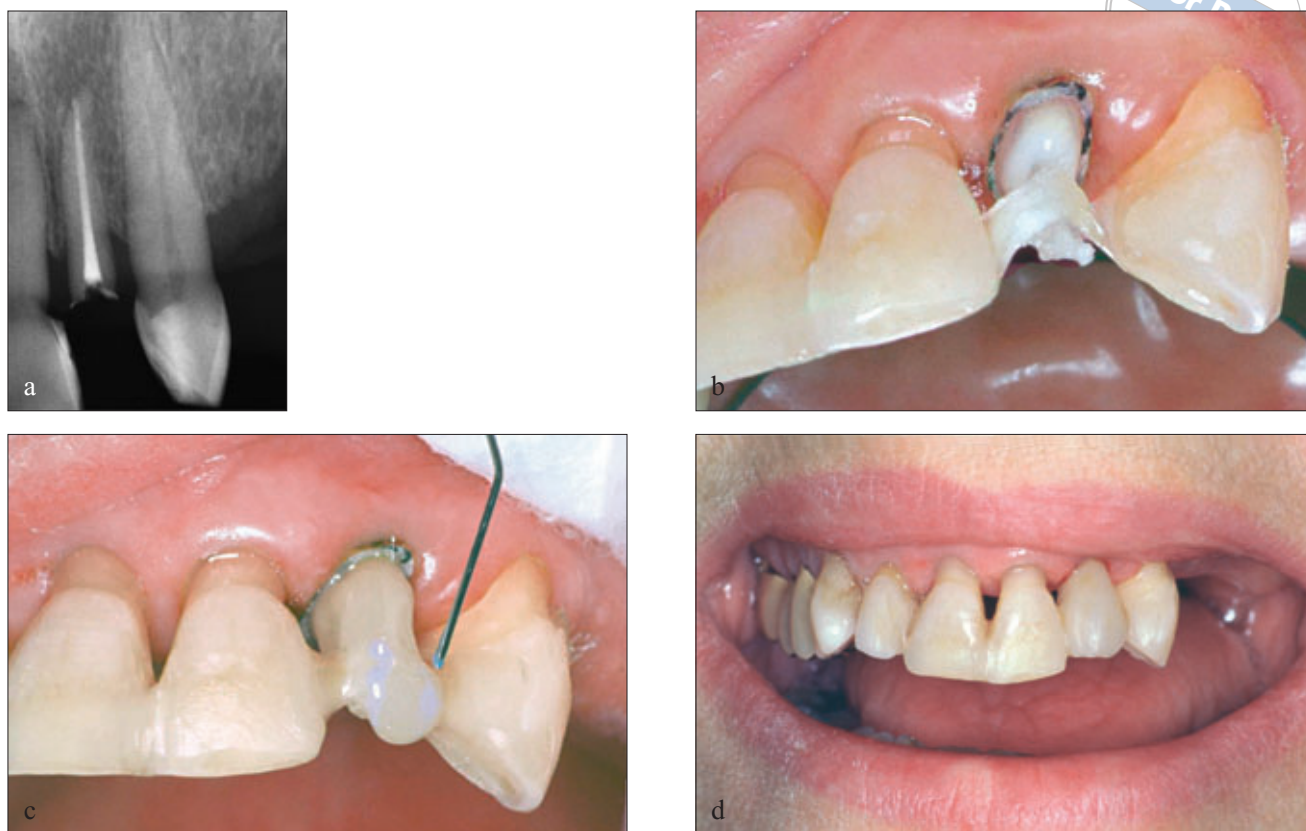


Fig 5 Root canal anchoring in combination with surface-retained splinting: (a) intra-oral periapical radiograph showing the remaining root of a canal treated maxillary lateral incisor with vertical bone loss; (b) additional fibres placed over the cemented fibre post in order to splint the tooth; (c) flow and hybrid composite resin used to build up the crown; (d) labial view of definitive restoration.

made with pre-impregnated unidirectional FRC. The rest of the treatment consisted of building up the composite crown, careful occlusal adjustment and fabrication of an occlusal splint (Fig 5). Compared with other post systems currently available, the FRC post has several benefits. It is suitable for direct and indirect technique, can be shaped into the form of the canal to achieve maximum bonding surface area, and provides a support for the crown due to the entirely filled pulp chamber. Furthermore, an FRC post offers the possibility of building the post and the bridge framework out of the same material to achieve maximum retention in special cases, reduce the risk of root fracture because of its natural elasticity, and require minimal dentine preparation^{24,25}.

Repair and reinforcement of a removable denture

The fracture of dentures made from acrylic resin (PMMA) is an unresolved problem and fractures occur even when metal strengtheners have been incorporated into the design²⁶. Before the immersion in acrylic, unidirectional or bidirectional FRC should be properly

placed in the margin where a crack will start or it has started (Fig 6). The reinforcement of removable dentures with FRC has worked to resolve the problem. Many clinical studies endorse the use of fibre reinforcement in removable dentures²⁷. The impact strength of a maxillary complete denture can be increased by a factor greater than 2 when reinforced with bidirectional FRC²⁸. However, just like in the case of any other fibre reinforcement, the positioning of fibre is of prime importance to achieve positive results^{3,27}. FRC can also be used as a framework for overdentures or implant-supported prostheses.

A surface-retained glass-fibre reinforced periodontal splint

Dr Varrel, Finland

The patient was a 69-year-old female who had several filled and extracted teeth due to periodontitis (mobility). She had generalised and localised bone loss in the molar areas and mandibular anterior area. After suitable periodontal treatment (scaling, root planing and curettage), a strong thin splint for the anterior area was prepared

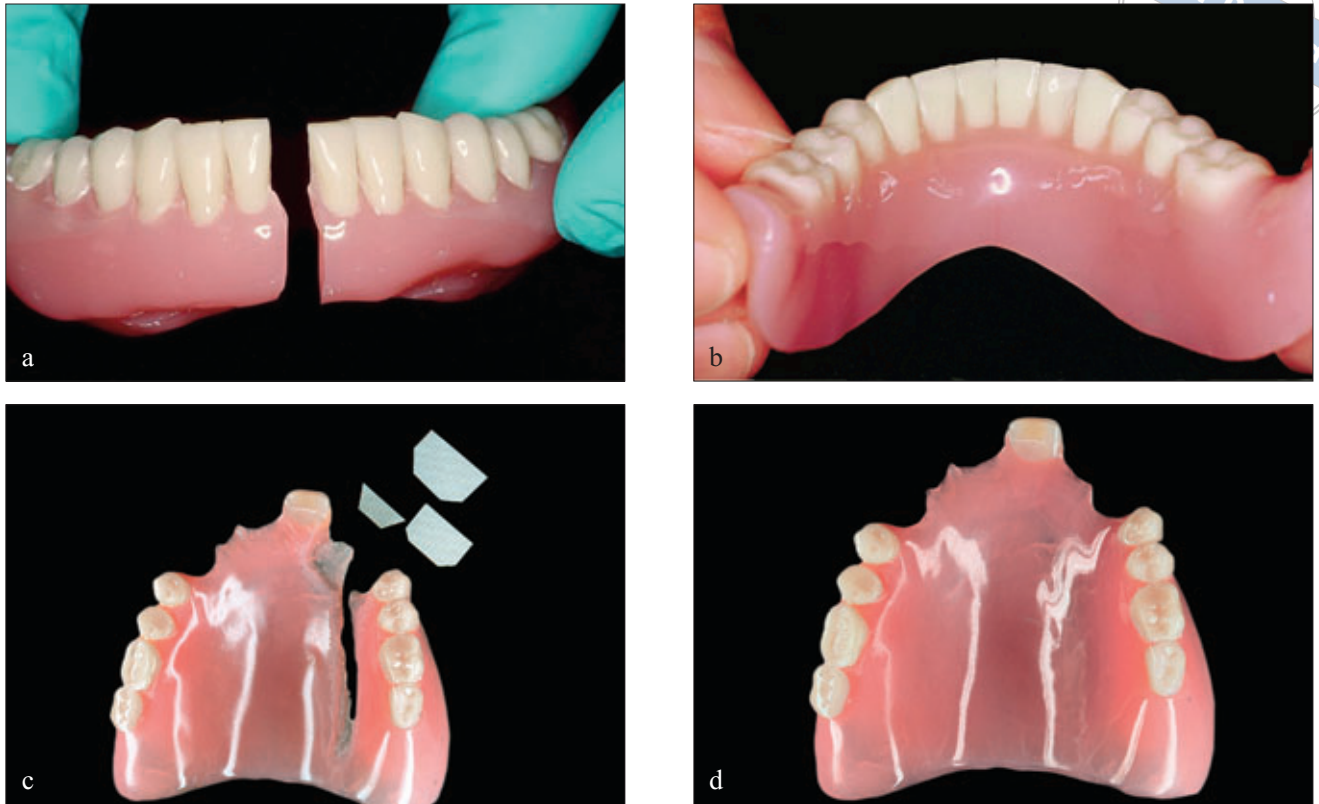


Fig 6 Repair and reinforcement of a removable denture: (a) fractured lower denture; (b) final form of the fibre-reinforced lower removable denture; (c) proper placement of continuous bidirectional FRC to the margin where an evaluated crack had occurred; (d) final form of the fibre-reinforced upper removable denture.

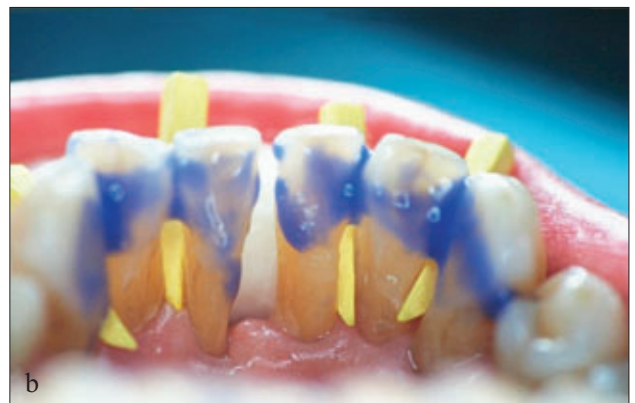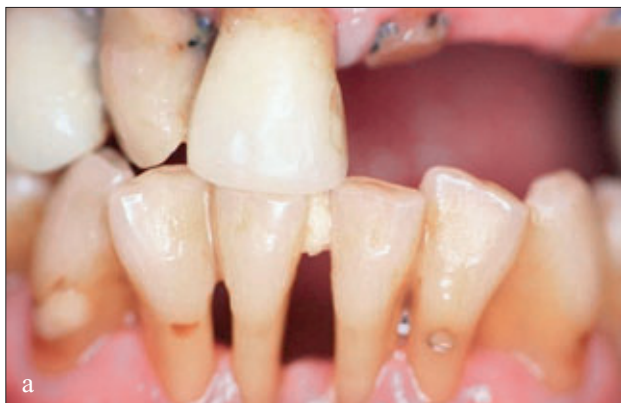using pre-impregnated unidirectional FRC. The thin splint facilitates good dental care.

When the fibre bundle was in place, it was covered entirely with flow composite. Finally, the patient's occlusion was checked and she was reminded of the use of interproximal brushes. The final result was functionally and aesthetically pleasing to the patient (Fig 7) (case has been published in the *Finnish Dental Journal* 18/2002).

Maxillary and mandibular bonded retainers after orthodontic therapy

Dr Cacciafesta, Italy

The patient was a 13-year-old female who had received fixed orthodontic therapy that lasted for 1 year and 5 months. After a complete correction of the crowding and reduction of overjet, it was planned to place maxillary and mandibular bonded retainers made of pre-



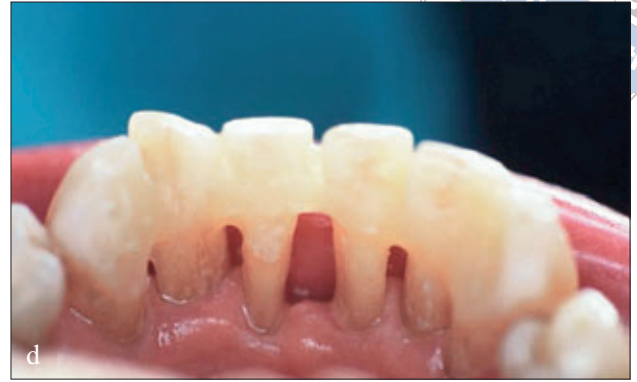
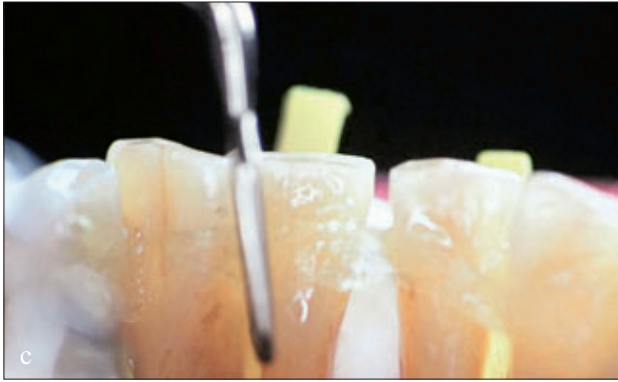
Fig 7 Surface-retained glass-fibre reinforced periodontal splint: (a) the situation before the periodontal treatment; (b) etched lingual surface of the teeth prior to adhesive bonding system; (c) continuous unidirectional fibres applied on the lingual surface of the teeth; (d) light-cured fibres (3 seconds on each tooth).

impregnated unidirectional FRC to prevent any possible relapse of crowding. Flowable composite covered the entire length of the fibre bundle, and also in the interproximal areas.

After curing, the retainer was polished, and the occlusion was checked to ensure that the fibre bundle was not placed into occlusion.

The same procedure was carried out in the mandible for fabricating a bonded canine-to-canine mandibular retainer (Fig 8).

Conclusion

The present article briefly described a glass-fibre reinforced composite that can be used in dentistry. Within the limitations of the clinical studies available to review, FRC is a promising material that gives clinicians alternative treatment options. However, multiyear clinical studies are currently in progress to determine the value and usefulness of the fibre-reinforced composite prosthesis as a long-term tooth replacement.

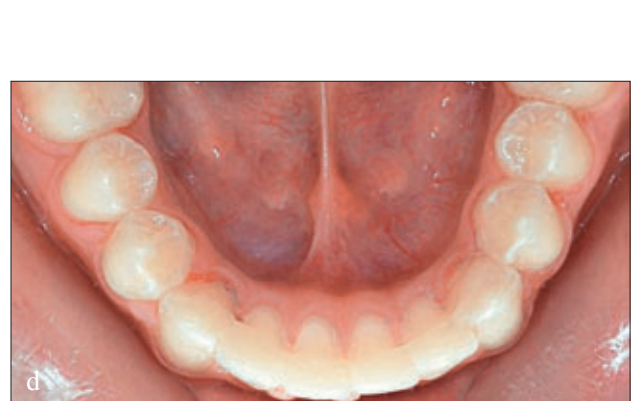
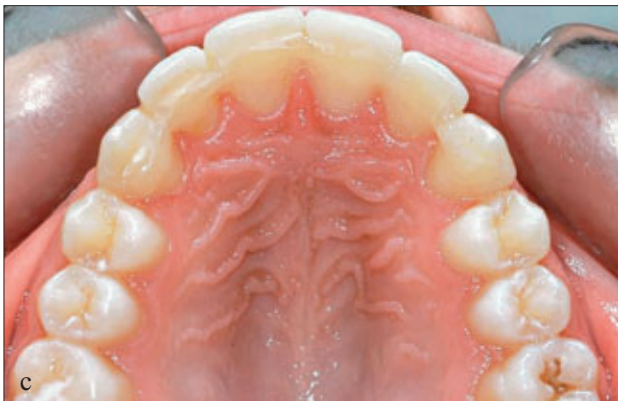
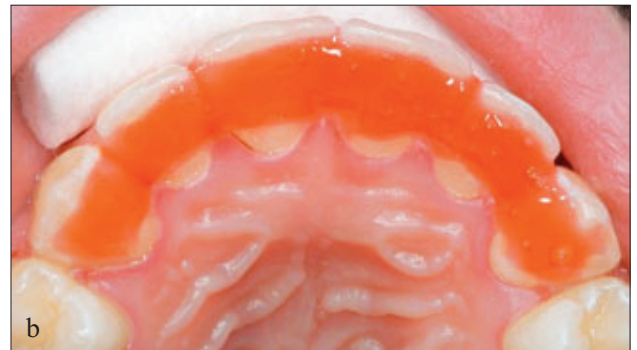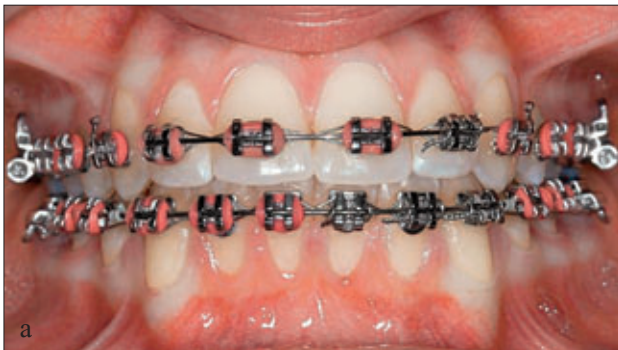Fig 8 Maxillary and mandibular bonded retainers after orthodontic therapy: (a) 1.5 year fixed orthodontic treatment; (b) etching of palatal surface with 37% phosphoric acid; (c) and (d) final result after insertion of fibres bundle.

References

1. Jokstad A, Gokce M, Hjortsjo C. A systemic review of the scientific documentation of fixed partial dentures made from fiber-reinforced polymer to replace missing teeth. *Int J Prosthodont* 2005;18:489-496.
2. Freilich MA, Meiers JS. Fiber-reinforced composite prostheses. *Dent Clin North Am* 2004;48:545-562.
3. Vallittu PK. A review of fiber-reinforced denture base resins. *J Prosthodont* 1996;5:270-276.
4. Edwards KL. An overview of the technology of fiber-reinforced plastics for design purposes. *Mater Des* 1998;19:1-10.
5. Arhun N, Arman A. Fiber-reinforced technology in multidisciplinary chairside approaches. *Indian J Dent Res* 2008;19:272-277.
6. Van Heumen CC, Krenlen CM, Bronkhorst EM, Lesaffre E, Creugers NH. Fiber-reinforced dental composite in beam testing. *Dent Mater* 2008;24:1435-1443.
7. Murphy J. Reinforced plastics handbook, 2nd ed. Oxford: Elsevier, 1998:265.
8. Vallittu PK. Comparison of the in vitro fatigue resistance of acrylic resin removable partial denture reinforced with continuous glass fibers or metal wires. *J Prosthodont* 1996;5:115-121.
9. Vallittu PK. Comparison of two different silane compounds used for improving adhesion between fibers and acrylic denture base material. *J Oral Rehabil* 1993;20:533-539.
10. Vallittu PK, Narva K. Impact strength of a modified continuous glass fiber-poly (methyl methacrylate). *Int J Prosthodont* 1997;10:42-48.
11. Vallittu PK, Lassila VP, Lappalainen R. Acrylic resin-fiber composite-part I: The effect of fiber concentration on fracture resistance. *J Prosthet Dent* 1994;71:607-612.
12. Stipho HD. Repair of acrylic resin denture base reinforced with glass fiber. *J Prosthet Dent* 1998;80:546-550.
13. Ladizesky NH, Cheng YY, Chow TW, Ward IM. Acrylic resin reinforced with chopped high performance polyethylene fiber properties and denture construction. *Dent Mater* 1993;9:128-135.
14. Dyer SR, Lassila LVJ, Jokinen M, Vallittu PK. Effect of fiber position and orientation on fracture load of fiber reinforced composite. *Dent Mater* 2004;20:947-955.
15. Vallittu PK. The effect of void space and polymerization time on transverse strength of acrylic-glass fiber composite. *J Oral Rehabil* 1995;22:257-261.
16. Miettinen VM, Vallittu PK. Water sorption and solubility of glass fiber-reinforced denture polymethyl methacrylate. *J Prosthet Dent* 1997;77:531-534.
17. Kangasniemi I, Vallittu P, Meiers J, Dyer SR, Rosentritt M. Consensus statement on fiber-reinforced polymers: current status, future directions, and how they can be used to enhance dental care. *Int J Prosthodont* 2003;16:209.
18. Vallittu PK. Survival rates of resin-bonded, glass fiber-reinforced composite fixed partial dentures with a mean follow-up of 42-months: a pilot study. *J Prosthet Dent* 2004;91:241-246.
19. Gohring TN, Roos M. Inlay-fixed partial dentures adhesively and reinforced by glass fiber: clinical and scanning electron microscopy analysis after five years. *Eur J Oral Sci* 2005;113:60-69.
20. Vallittu PK. Some aspects of the tensile strength of unidirectional glass fiber-polymethyl methacrylate composite used in dentures. *J Oral Rehabil* 1998;25:100-105.
21. Lastumäki TM, Lassila LV, Vallittu PK. The semi-interpenetrating polymer network matrix of fiber-reinforced composite and its effect on the surface adhesive properties. *J Mater Sci Mater Med* 2003;14:803-809.
22. Farah JW. A 4-years clinical performance of Sculpture/Fiberkor. *Dental Advisor* 2001;18:6-7.
23. Freilich MA, Meiers JC, Duncan JP, Eckrote KA, Goldberg AJ. Clinical evaluation of fiber-reinforced fixed bridges. *J Am Dent Assoc* 2002;133:1524-1534.
24. Bell AM, Lassila LV, Kangasniemi I, Vallittu PK. Bonding of fiber-reinforced composite post to root canal dentin. *J Dent* 2005;33:533-539.
25. Lassila LV, Tanner J, Bell AM, Narva K, Vallittu PK. Flexural properties of fiber reinforced root canal posts. *Dent Mater* 2004;20:29-36.
26. Vallittu PK, Lassila VP, Lappalainen R. Evaluation of damage to removable dentures in two cities in Finland. *Acta Odontol Scand* 1993;51:363-369.
27. Narva KK, Vallittu PK, Helenius H, Yli-Urpo A. Clinical survey of acrylic resin removable denture repairs with glass-fiber reinforcement. *Int J Prosthodont* 2001;14:219-224.
28. Kim SH, Watts DC. The effect of reinforcement with woven E-glass fibers on the impact strength of complete dentures fabricated with high-impact acrylic resin. *J Prosthet Dent* 2004;91:274-280.