

# Endodontic Treatments of Mandibular First Molar with Middle Mesial Canal: Two Case Reports

Qun LU<sup>1</sup>, Ping WANG<sup>1</sup>, Bo YANG<sup>1</sup>, Xiao Jing LIU<sup>1</sup>, Shu Yong WANG<sup>1</sup>, Qing YU<sup>1</sup>

*The mandibular first molars mostly have two mesial canals. In this report, two cases of mandibular first molars with three mesial canals are presented. The middle mesial canal was detected under endodontic microscope and further confirmed by cone-beam computed tomography and angled radiography, respectively. The purpose of this paper was to highlight the possibility of an aberrant root canal in a mandibular first molar and to help reduce the failure rates of the dental pulp treatment of the mandibular first molar.*

**Key words:** mandibular first molar, middle mesial canal, root canal morphology

The mandibular first molar is the earliest eruption of the permanent teeth, which suffers the highest rate of dental caries. It is the tooth that most often requires root canal treatment in clinic. There are various factors influencing the effect of root canal therapy. One is the inability to identify aberrant root canals, resulting in inadequate cleaning and shaping. The mandibular first permanent molars usually have three canals, including two in the mesial root and another one or two in the distal root (with radix entomolaris<sup>1</sup>). So far, the existence of a morphological variation about the mesial root with an additional middle canal has rarely been reported<sup>2-9</sup>.

To the best of our knowledge, there have been no clinical cases reported about middle mesial (MM) in the Chinese population to date. In this paper, we report the clinical root canal treatment of mandibular first molars with three canals in their mesial root.

## Case report

### Case 1

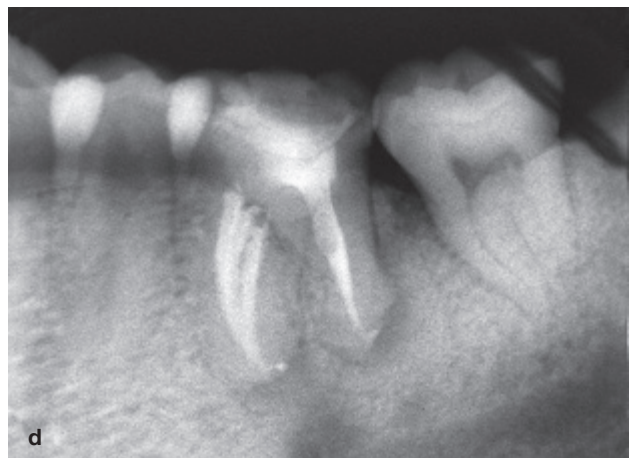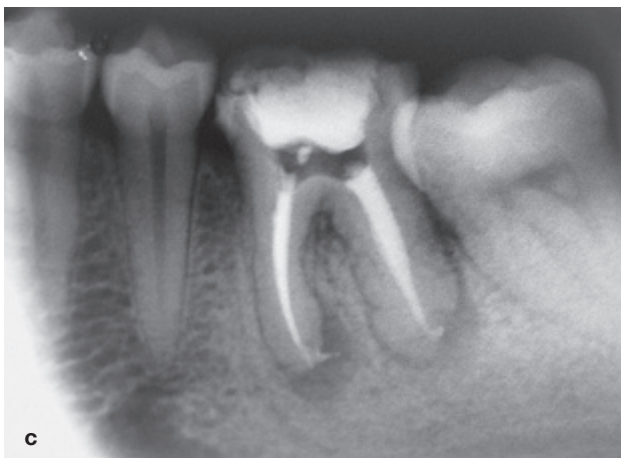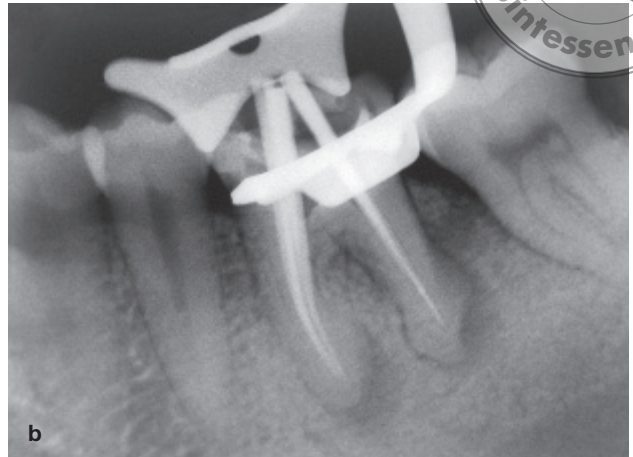
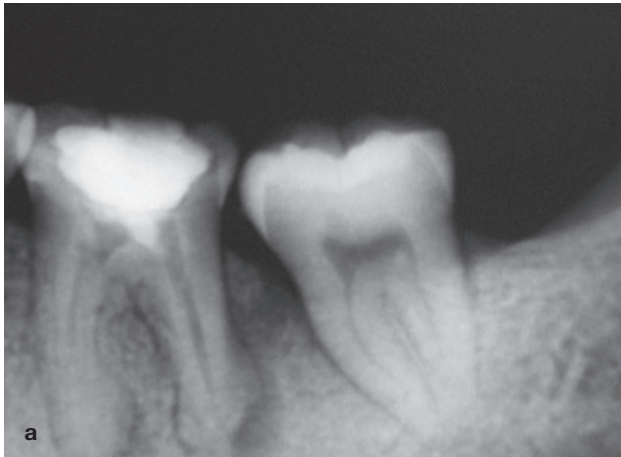
A 28-year-old man was referred to our department with a chief complaint of a severe pain in his left mandibular

first molar that he had had for the past 10 days. His medical history was regarded as noncontributory. Clinical examination showed the existence of a restoration and secondary caries around it in tooth 19 with tenderness on percussion. A fistulae and swelling were observed in the soft tissues there. No periodontal pockets were presented. A negative response of electrical pulp testing (Vitality Scanner; Analytic Technology) and a periapical radiolucency of radiographic examination (Fig 1a) led to a diagnosis of chronic periapical peridontitis. Then endodontic treatment was planned.

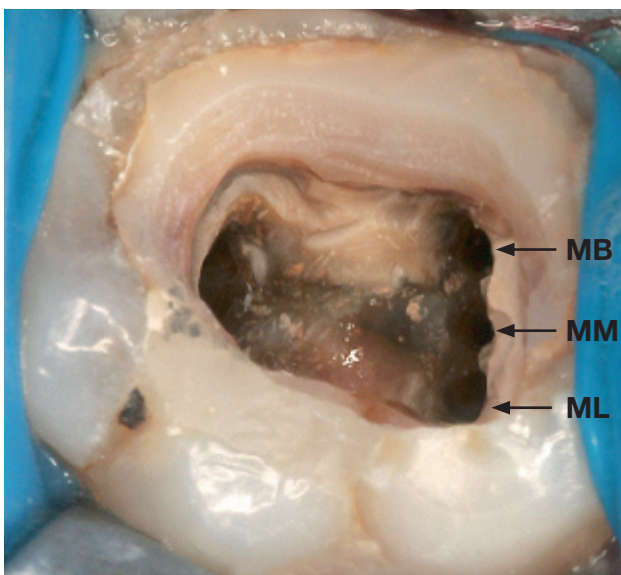
With the patient's consent, a rubber dam was placed, all filling materials and carious tissue were removed, and a trapezoidal access was prepared. Four root canal orifices were first observed, including mesiobuccal (MB), mesiolingual (ML), distobuccal and distolingual. The root canals were cleaned and shaped using stainless steel hand K-files, and Protaper nickel-titanium rotary instrumentation (Dentsply Maillefer) under copious irrigation with 5.25% sodium hypochlorite. During the course, a tiny orifice was detected between the MB and ML with an endodontic explorer DG-16 (Dentsply Maillefer, Ballaigues, Switzerland) under endodontic microscope (Carl Zeiss, Oberkochen, Germany). The clinician tried to insert a no. 15 K-file through the orifice, go deep into it and squeezed, so the existence of a middle mesial (MM) canal in a line was considered (Fig 2). The three mesial root canals were arrayed in a line. The additional canal (MM) was cleaned and shaped using the same technique as the other canals. The working length was determined with an electronic apex locator (RootZX; Morita)

1 Department of Operative Dentistry and Endodontic, College of Stomatology, Fourth Military Medical University, Xi'an, Shaanxi, People's Republic of China

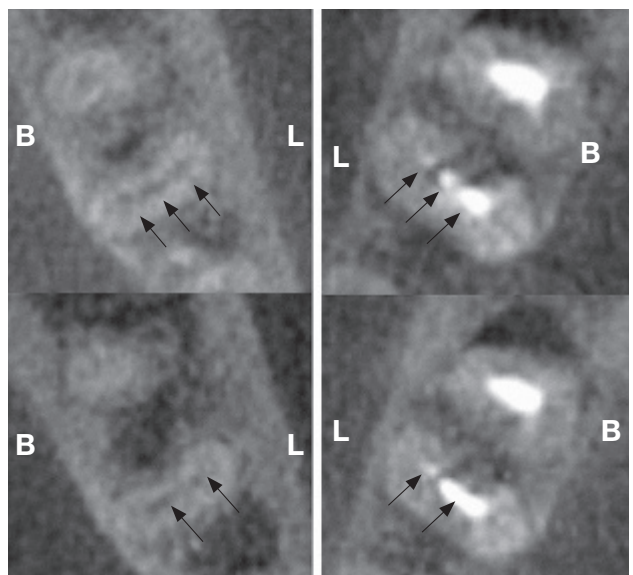
**Corresponding author:** Dr Qing YU, Department of Operative Dentistry & Endodontics, School of Stomatology, Fourth Military Medical University, 145 Chang-le Xi Road, Xi'an, 710032, P.R. China. Fax: 86-29-84776476; E-mail: qingyu@fmmu.edu.cn



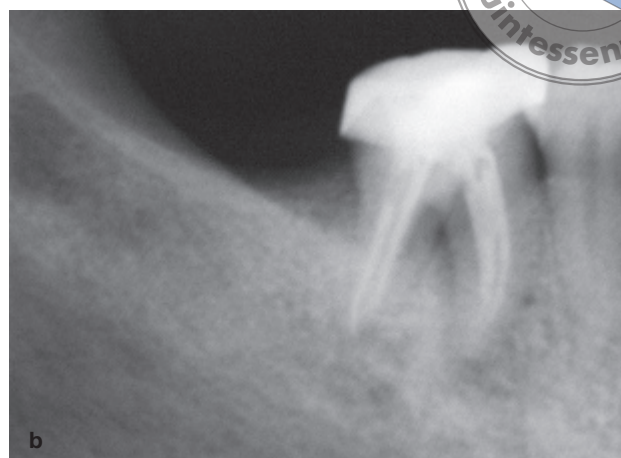
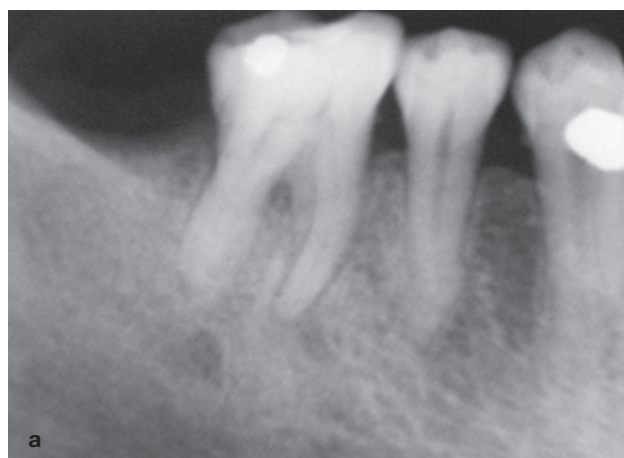
**Fig 1** Mandibular first right molar with five root canals (case one). (a) Preoperative radiograph. (b) Radiograph with five gutta-percha points. (c) Postobturation radiograph. (d) One month follow-up.



**Fig 2** Pulpal floor showing three mesial canal orifices of case one.



**Fig 3** CBCT images showing three canals, MM merged with MB in left mandibular first molar (case one).



**Fig 4** Radiographs of case two (a) Preoperative radiograph. (b) Postobturation radiograph.

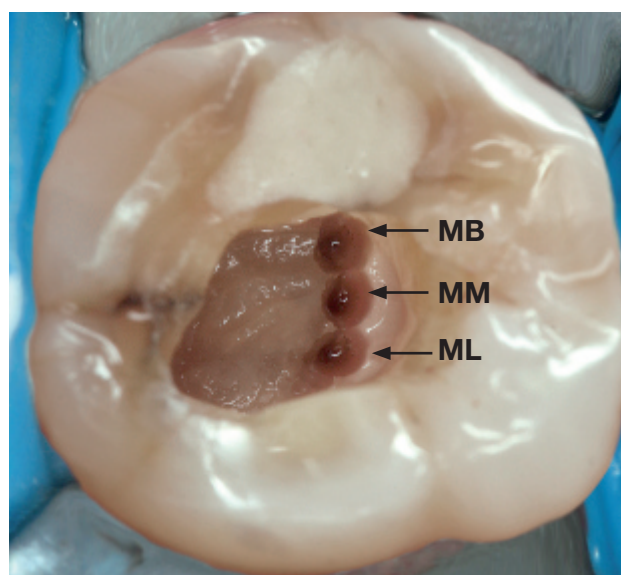
and subsequently ensured with a gutta-percha cone fit radiograph (Fig 1b). Before the access was sealed with Cavit (ESPE), the canals were dried and inserted with calcium hydroxide-based intracanal dressing. One week later, the tooth was symptomless, and the sinus tract became concrecent. The canals were obturated with gutta-percha cone using warm vertical condensation technique (B&L). Finally the tooth was restored with composite resin Filtek P60 (3M ESPE). Postoperative radiographs were taken and found the curative effect satisfactory (Figs 1c and 1d). The patient experienced no posttreatment discomfort and was referred for appropriate coronal restoration.

For further information about the root canal configuration of the tooth and its contralateral namesake tooth, cone beam computed tomography (CBCT) was performed after obturation with the informed consent from the patient. The images (Fig 3) revealed that the MM canal of tooth 19 was confluent with the MB canal. Interestingly, three mesial canals were also observed in the contralateral tooth.

### Case 2

A 55-year-old woman was referred to our department for endodontic treatment for the right mandibular first molar. Her medical history was noncontributory. Clinical examination showed a cotton ball with haemic effusion in the pulp chamber. No periodontal pockets were presented. Radiographic examination showed periapical radiolucency (Fig 4a). A diagnosis of irreversible pulpitis was made and an endodontic treatment was planned.

The access cavity was modified to expose pulp chamber clearly. Examination of the chamber floor with



**Fig 5** Pulpal floor showing three mesial canal orifices of case two.

an endodontic explorer DG-16 (Dentsply Maillefer) under an endodontic microscope (Carl Zeiss) showed 5 root canal orifices, three mesial canals and two distal canals (Fig 5). The root canals were cleaned, shaped and restored using the same instruments and materials as in Case 1. Ultrasonic irrigation (EMS, miniMaster piezon scaler) was involved in the root canal treatment. The treatment was completed in one visit. Then postoperative radiographs were taken to observe the curative effect (Fig 4b), indicating that the patient received appropriate coronal restoration.



## Discussion

Morphological knowledge of the root canal system is an indispensable element that influences the outcome of endodontic treatment. Mandibular first molars, which play a very important role in all aspects, own a complex root canal system. Although the concept of two canals in the mesial root of a mandibular first molar is commonly accepted. Endodontic treatment of the medial mesial canal usually used to be overlooked in clinical practice. Yesilsoy et al<sup>4</sup> reported 2 cases that needed endodontical retreatment due to failing to recognise the middle mesial canal. The incidence of MM reported in literature ranges from 2.07% to 15% *in vivo*<sup>9,10</sup>. Additionally, Beatty and Iterian<sup>11</sup> have reported on more obscure cases in which a third canal was located in the distal root. Martinez-Berna and Bandanelli showed two cases with six canals<sup>12</sup>. Knowledge of anatomy morphology of the mandibular first molar with a middle mesial canal should be emphasised.

In the 2 cases described above, an additional MM canal was presented with a separated root canal orifice. The distance between the MB orifice and the ML orifice is relatively longer than normal. These three orifices were along a buccal-lingual-wise line. The accessory middle mesial canal orifice was detected closer to the ML canal, and therefore, clinicians should specifically search for any hidden middle mesial canal starting from the ML canal orifice and progress systematically along the subpulpal groove towards the MB canal orifice<sup>13</sup>. Locating and identifying a middle mesial canal may be a challenge for clinicians, because orifices of the accessory root canals are too small to be observed by naked eye. In the present cases, the additional mesial canal orifices were detected with the aid of dental microscope, which the methods were previously suggested by Friedman et al<sup>13</sup>.

Radiographs with endodontic files showed that both of the present two MM canals were merged with the MB canal, and the anastomotic area could be observed at the apical third of the root. The confluence of the middle mesial canal was consistent with one of the categories classified by Pomeranz et al<sup>14</sup>. CBCT, one of the new diagnostic imaging modality, can not only provide 3-dimensionnal images of axial, transverse and sagittal sections, but also obtain comprehensive information of root canal configuration in the offending tooth as well as in the contralateral tooth. With the wide use of CBCT, the curative rate of aberrant roots of canal middle mesial canals may be increased significantly in endodontic treatment.

Here we presented two cases of mandibular first molars with an additional middle mesial canal.

Consideration should be paid to realize the possibility of MM. It is necessary for the meticulous examination of the pulp chamber before filling canals using a magnifying device. For example, an endodontic microscope is used to detect the possible omitted canal orifice. Though radiography provides only a 2-dimensional, angled radiography with endodontic files is still valuable for diagnosing an aberrant root canal. If this does not work, CBCT is recommended for further confirmation<sup>15</sup>.

## Acknowledgement

This study was supported in part by grants from the National Natural Scientific Foundation of China (30870636).

## References

1. Christie WH, Thompson GK. The importance of endodontic access in locating maxillary and mandibular molar canals. *J Can Dent Assoc* 1994;60:527–532, 535–536.
2. Min K. Clinical management of a mandibular first molar with multiple mesial canals: a case report. *J Contemp Dent Pract* 2004;5: 142–149.
3. La SH, Jung DH, Kim EC, Min KS. Identification of independent middle mesial canal in mandibular first molar using cone-beam computed tomography imaging. *J Endod* 2010;36:542–545.
4. Yesilsoy C, Porras O, Gordon W. Importance of third mesial canals in mandibular molars: report of 2 cases. *Oral Surg Oral Med Oral Pathol Oral Radiol Endod* 2009;108:e55–58.
5. Jacobsen EL, Dick K, Bodell R. Mandibular first molars with multiple mesial canals. *J Endod* 1994;20:610–613.
6. Baugh D, Wallace J. Middle mesial canal of the mandibular first molar: a case report and literature review. *J Endod* 2004;30:185–186.
7. Holtzmann L. Root canal treatment of a mandibular first molar with three mesial root canals. *Int Endod J* 1997;30:422–424.
8. Navarro LF, Luzi A, Garcia AA et al. Third canal in the mesial root of permanent mandibular first molars: review of the literature and presentation of 3 clinical reports and 2 *in vitro* studies. *Med Oral Patol Oral Cir Bucal* 2007;12:E605–609.
9. Fabra-Campos H. Unusual root anatomy of mandibular first molars. *J Endod* 1985;11:568–572.
10. Goel N, Gill K, Taneja J. Study of root canals configuration in mandibular first permanent molar. *J Indian Soc Pedod Prev Dent* 1991;8:12–14.
11. Beatty RG, Iterian CM. A mandibular first molar with five canals: report of case. *J Am Dent Assoc* 1985;111:769–771.
12. Martinez-Berna A, Badanelli P. Mandibular first molars with six root canals. *J Endod* 1985;11:348–352.
13. Karapinar-Kazandag M, Basrani BR, Friedman S. The operating microscope enhances detection and negotiation of accessory mesial canals in mandibular molars. *J Endod* 2010;36:1289–1294.
14. Pomeranz HH, Eidelman DL, Goldberg MG. Treatment considerations of the middle mesial canal of mandibular first and second molars. *J Endod* 1981 1981-12-01;7:565–568.
15. Kottoor J, Velmurugan N, Sudha R, Hemamalathi S. Maxillary first molar with seven root canals diagnosed with cone-beam computed tomography scanning: a case report. *J Endod* 2010;36:915–921.